

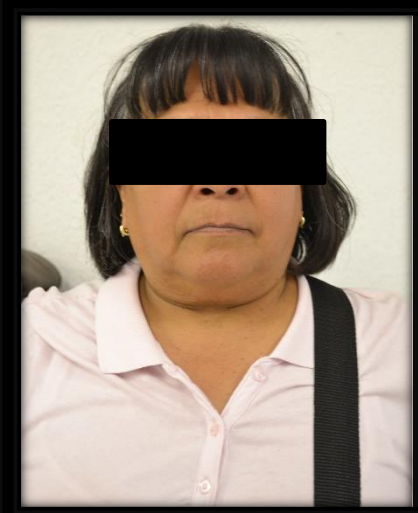TRATAMIENTO ALTERNATIVO DE IMPLANTES CON CONDICIONES ANATÓMICAS NO IDEALES Y MAL POSICIONADOS. PRESENTACIÓN DE UN CASO CLÍNICO.

C.D. Est.E.P. Joel Armando Garcia Quiñones.
C.D.E.P. Francisco Javier Rivera Mendoza.

Introducción.

- La Implantología dental en crecimiento.
- Garantizar su éxito y mejorar la calidad.
- No excenta al operador del error.
- Rectificación segura y predecibles.
- La supervivencia del implante.

Ficha de Identidad.



Nombre: Rosa María.

Edad: 58 años.

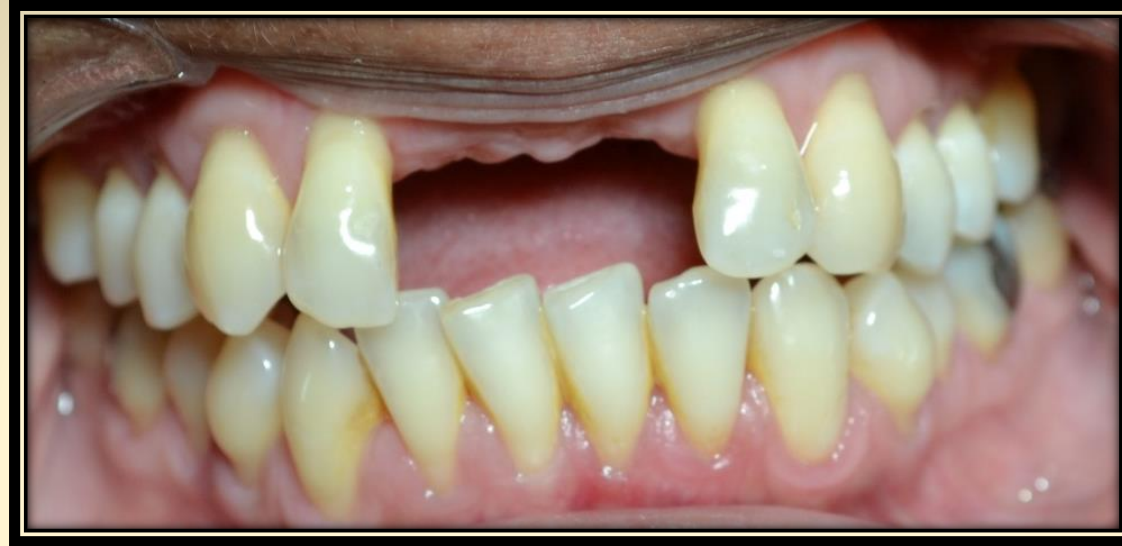Motivo de consulta: "Colocar cicatrizales para implante".

Antecedentes Patológicos: Sin Dato Patológico.  ASA I.

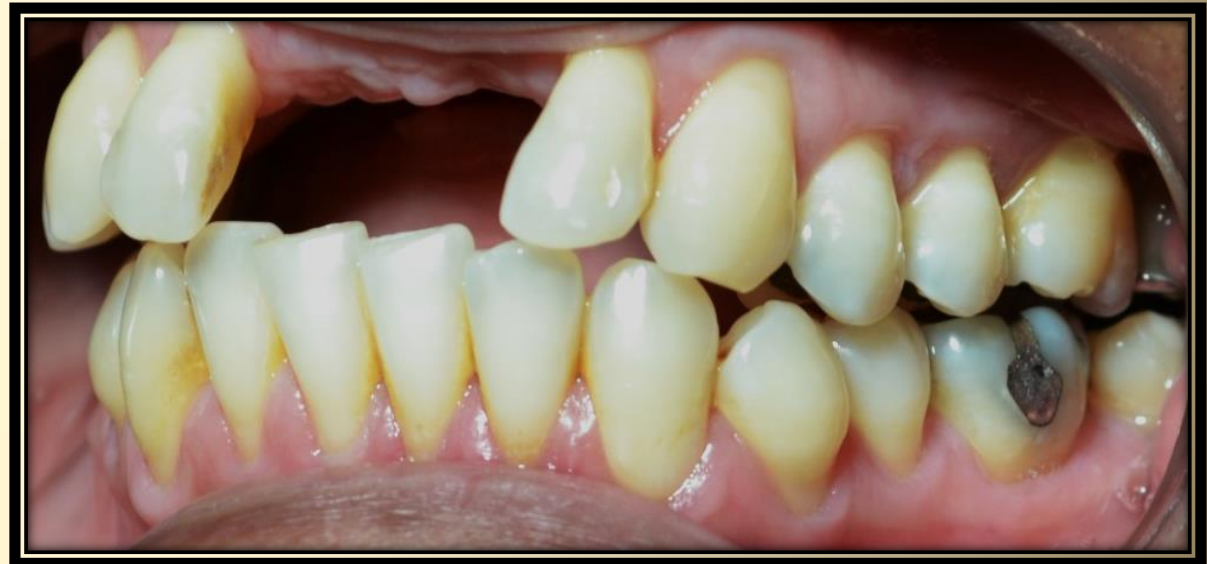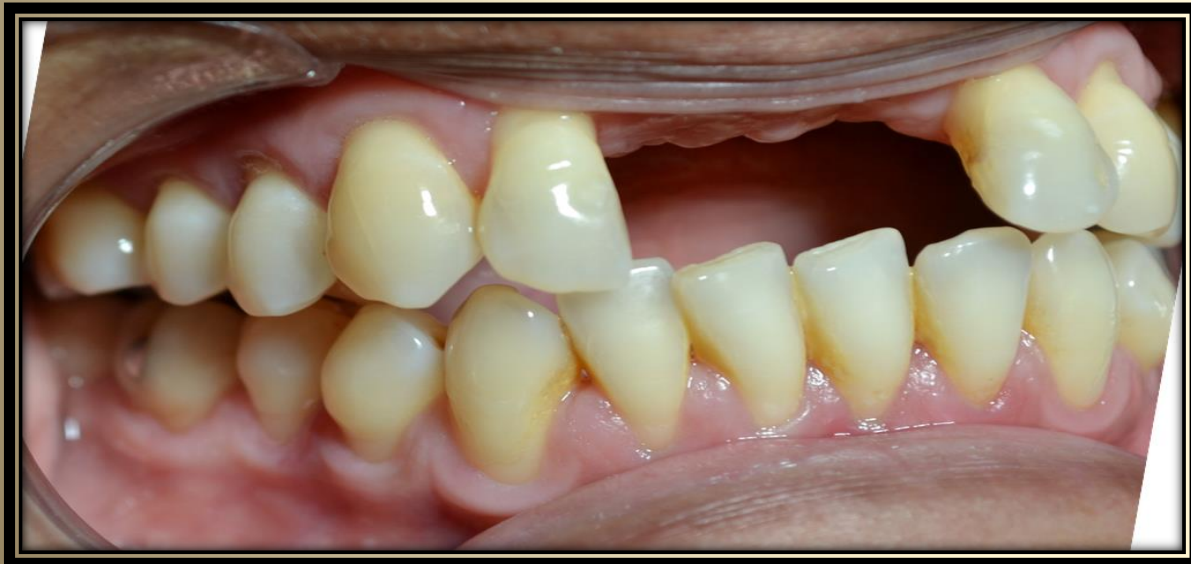Diagnóstico(s): Periodontitis crónica localizada leve.
Implantes con translucidez sobre mucosa alveolar.
Recesiones clase III Miller.

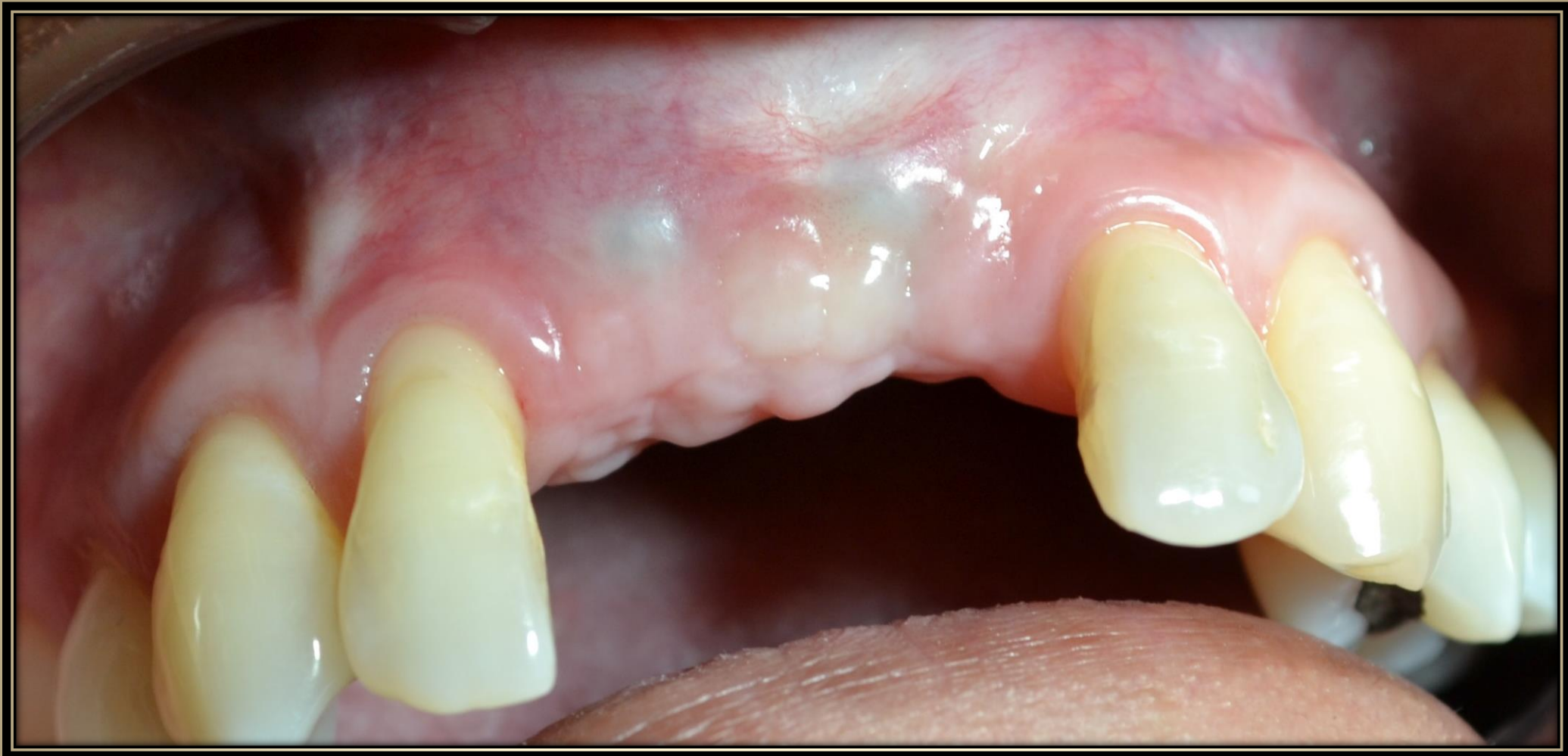FRONTAL

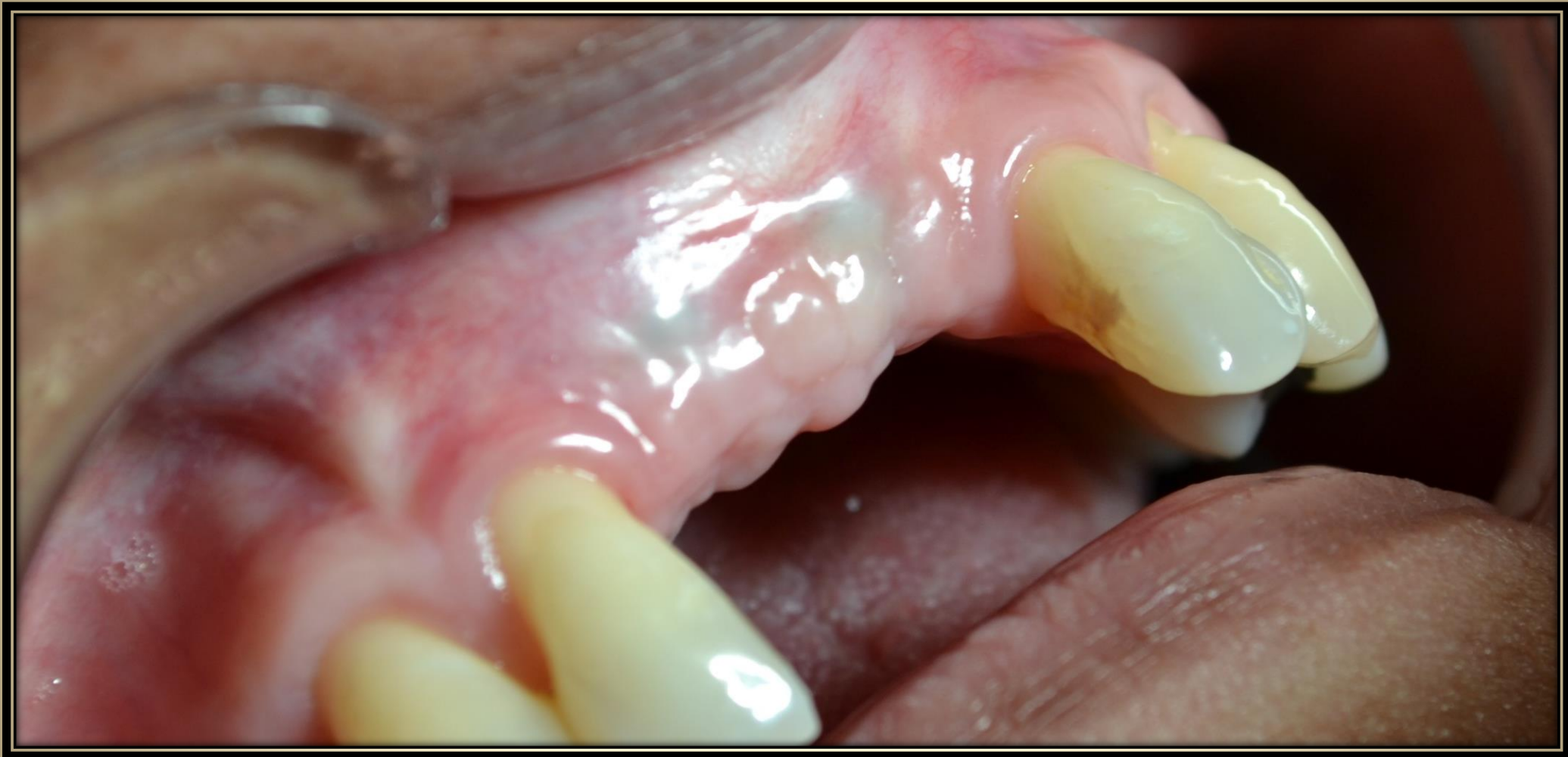DERECHO



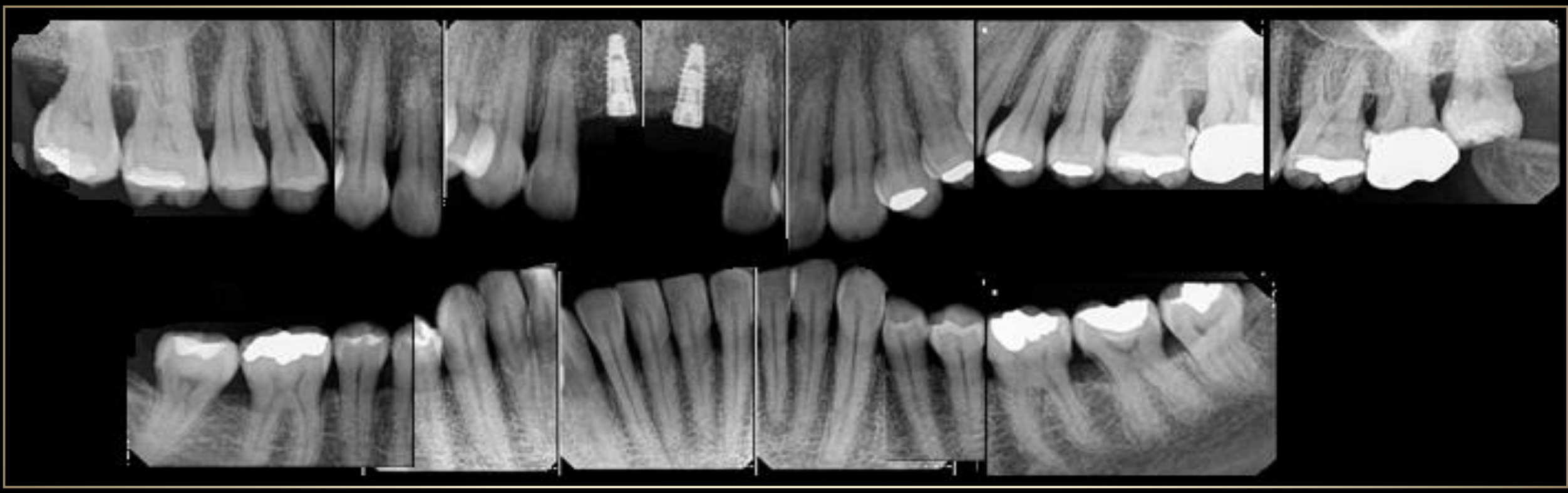
IZQUIERDO







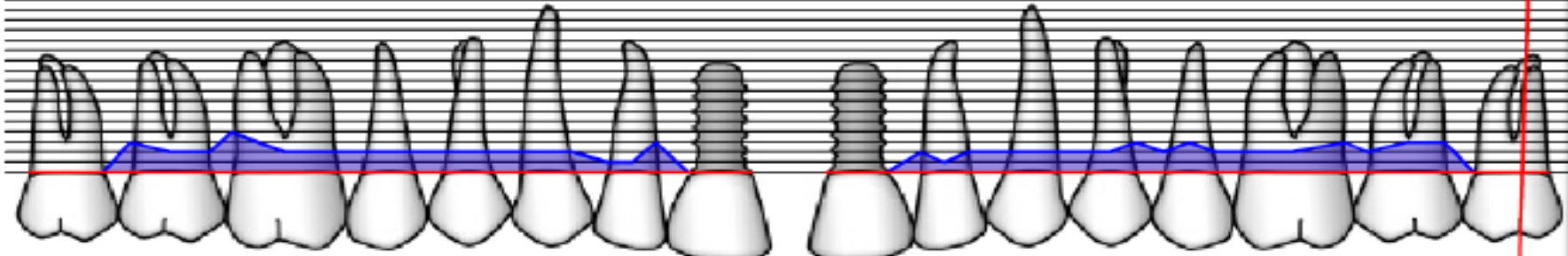
Estudio radiográfico periapical



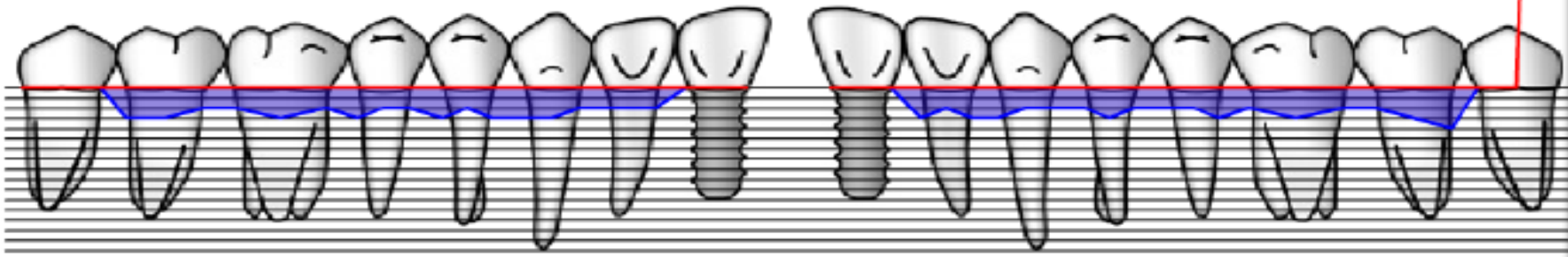
	18	17	16	15	14	13	12	11
Movilidad	0	0	0	0	0	0	1	0
Implante								■
Furca								
Sangrado al sondaje		■	■	■	■			
Placa								
Margen gingival	0 0 0	0 0 0	0 0 0	0 0 0	0 0 0	0 0 0	0 0 0	0 0 0
Profundidad de sondaje	0 0 0	3 2 2	4 2 2	2 2 2	2 2 2	2 2 2	1 1 3	0 0 0

	21	22	23	24	25	26	27	28
Movilidad	0	0	0	0	0	0	0	0
Implante	■							
Furca								
Sangrado al sondaje					■	■	■	■
Placa								
Margen gingival	0 0 0	0 0 0	0 0 0	0 0 0	0 0 0	0 0 0	0 0 0	0 0 0
Profundidad de sondaje	0 0 0	2 1 2	2 2 2	2 2 3	2 3 2	2 2 3	2 3 3	0 0 0

Bucal



Palatino



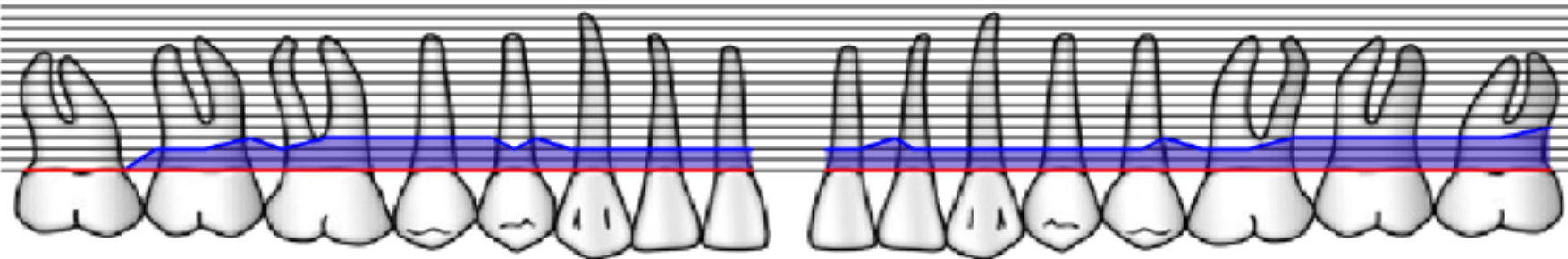
Margen gingival	0 0 0	0 0 0	0 0 0	0 0 0	0 0 0	0 0 0	0 0 0	0 0 0
Profundidad de sondaje	0 0 0	3 3 2	2 3 2	3 2 2	3 2 3	3 3 2	2 2 2	0 0 0
Placa								
Sangrado al sondaje		■	■	■	■			
Furca								
Nota	Ausente							

Margen gingival	0 0 0	0 0 0	0 0 0	0 0 0	0 0 0	0 0 0	0 0 0	0 0 0
Profundidad de sondaje	0 0 0	3 2 3	3 2 2	2 3 2	2 2 3	2 3 2	2 3 4	0 0 0
Placa								
Sangrado al sondaje					■	■		
Furca								
Nota								

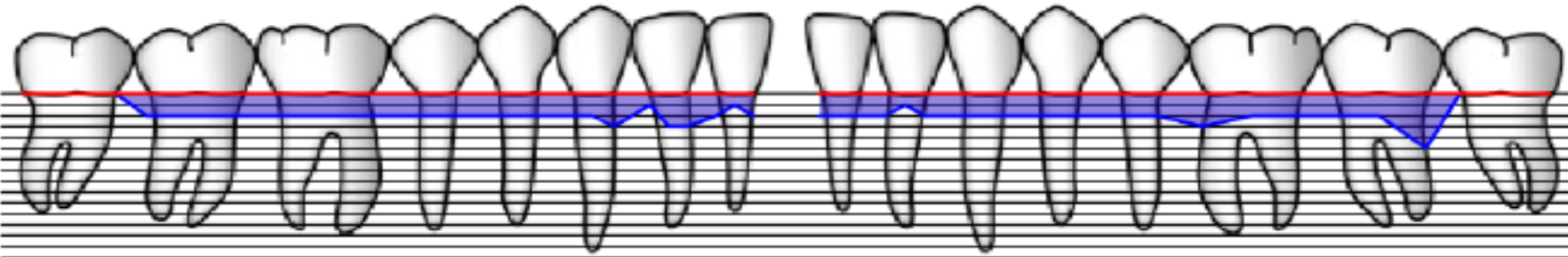
Media de prof. de sondaje = 1.9 mm Media de nivel de inserción= NaN mm 0% Placa 9% Sangrado al sondaje

Nota																	
Furca																	
Sangrado al sondaje																	
Placa																	
Margen gingival	0 0 0	0 0 0	0 0 0	0 0 0	0 0 0	0 0 0	0 0 0	0 0 0	0 0 0	0 0 0	0 0 0	0 0 0	0 0 0	0 0 0	0 0 0	0 0 0	
Profundidad de sondaje	0 0 0	2 2 3	2 3 3	3 3 3	3 2 3	2 2 2	2 2 2	2 2 2	2 2 3	2 2 3	3 3 3	3 3 3	3 3 3	3 3 3	3 3 3	4	

Lingual

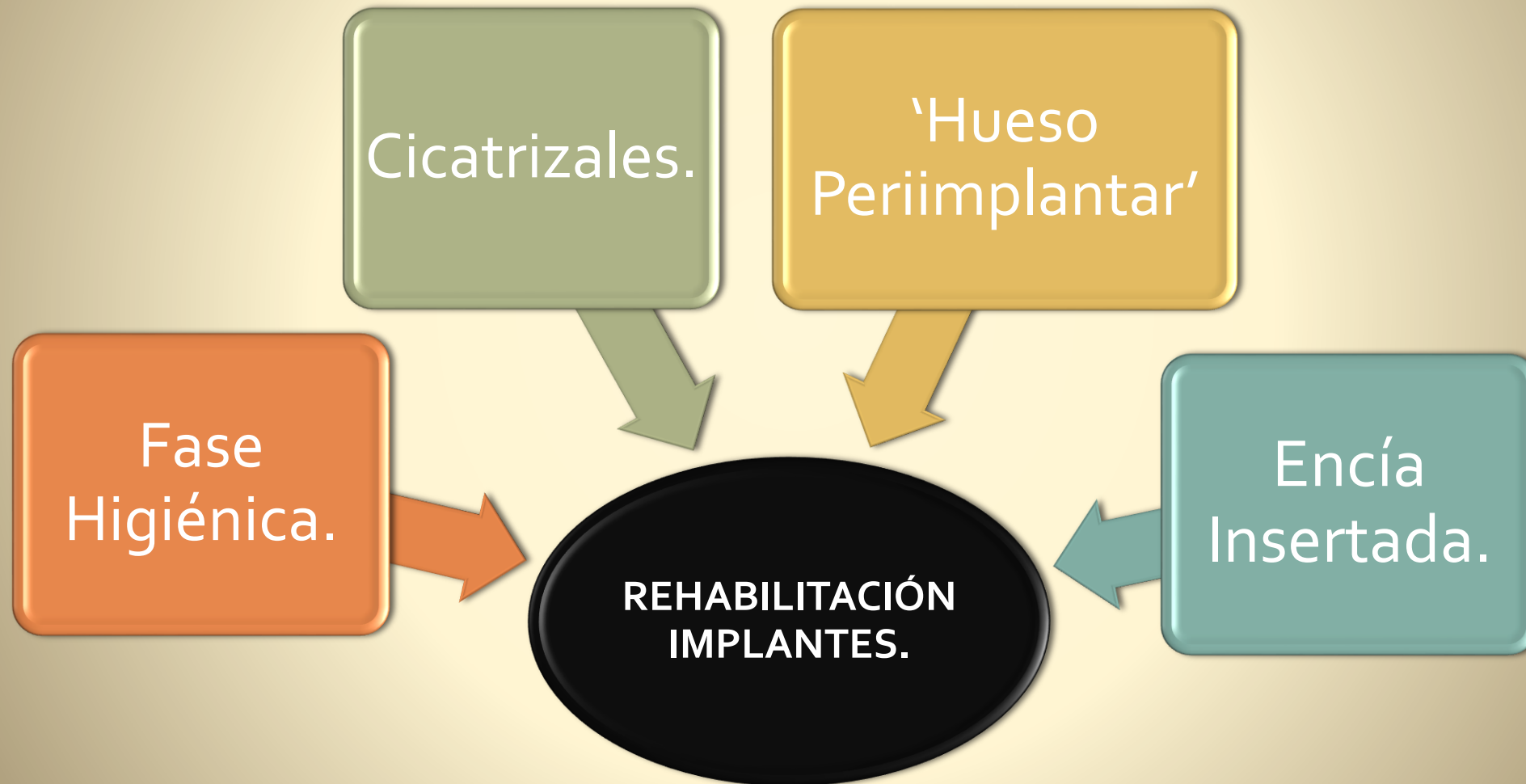

Bucal

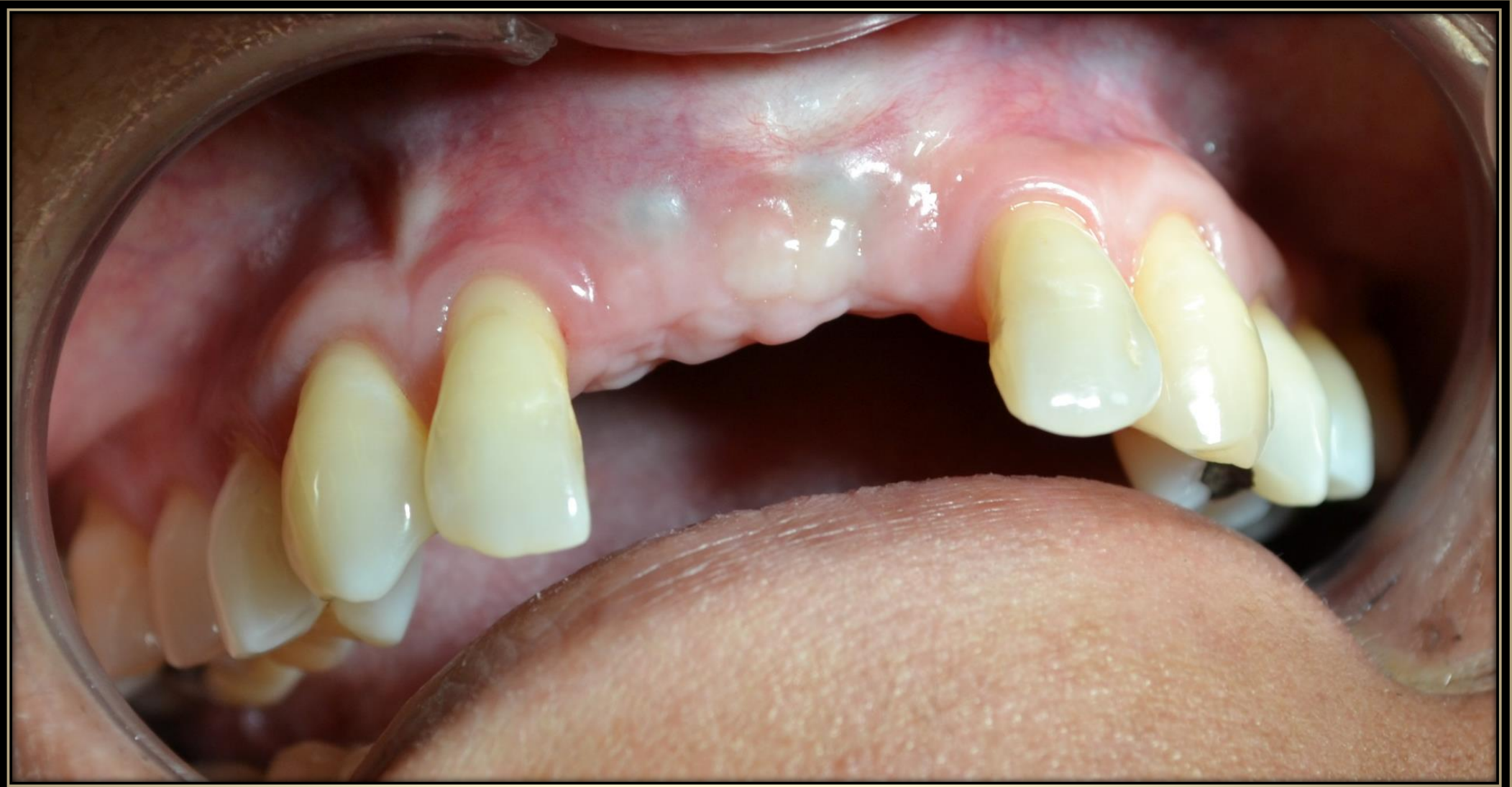

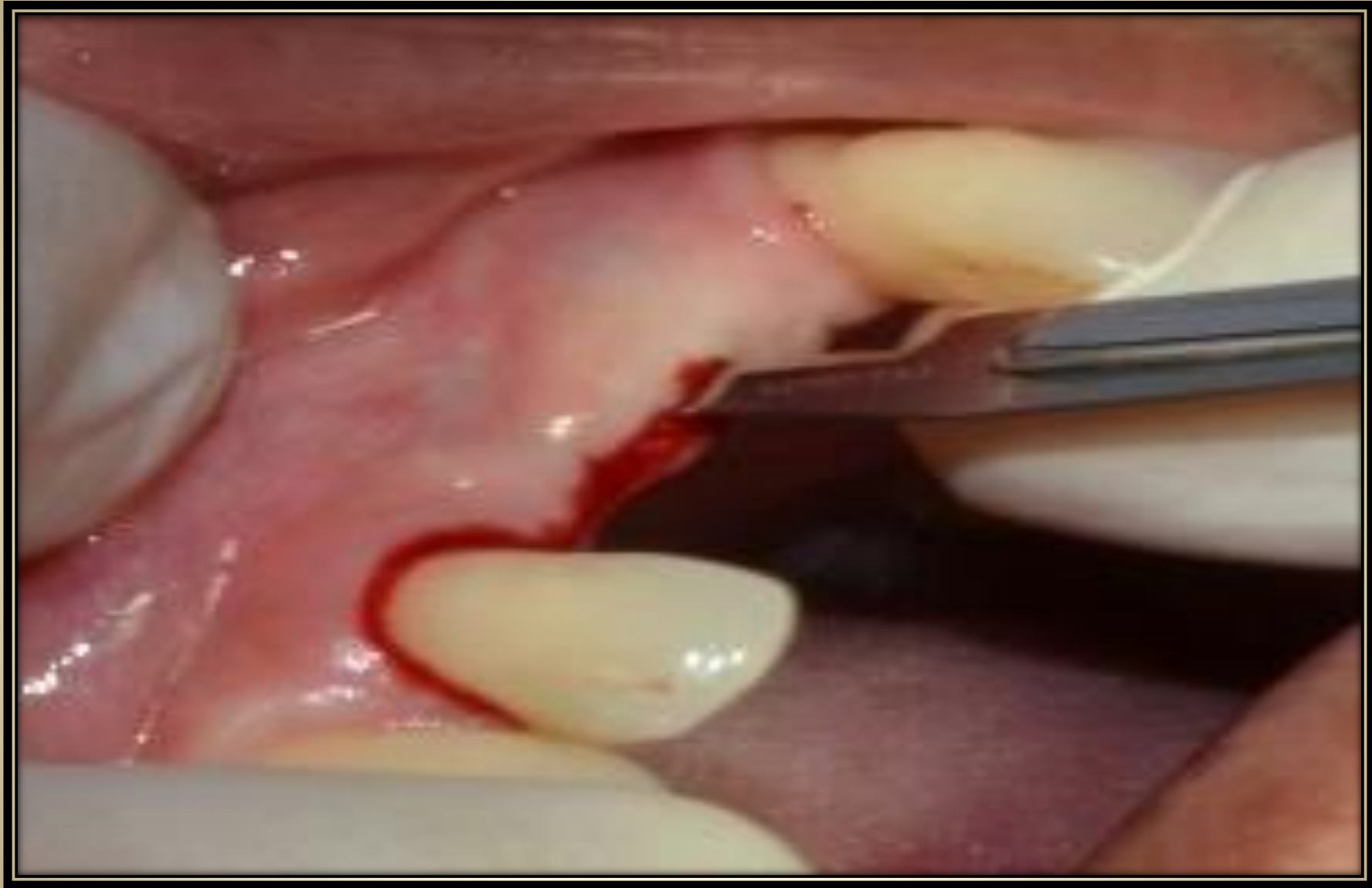Margen gingival	0 0 0	0 0 0	0 0 0	0 0 0	0 0 0	0 0 0	0 0 0	0 0 0	0 0 0	0 0 0	0 0 0	0 0 0	0 0 0	0 0 0	0 0 0	0 0 0
Profundidad de sondaje	0 0 0	2 2 2	2 2 2	2 2 2	2 2 2	2 2 3	1 3 3	2 1 2	2 2 2	2 2 2	2 2 2	3 2 2	2 2 5	0 0 0	0 0 0	0 0 0
Placa																
Sangrado al sondaje																
Furca																
Implante																
Movilidad	0	0	0	0	0	0	0	1	0	0	0	0	0	0	0	0
	48	47	46	45	44	43	42	41	31	32	33	34	35	36	37	38

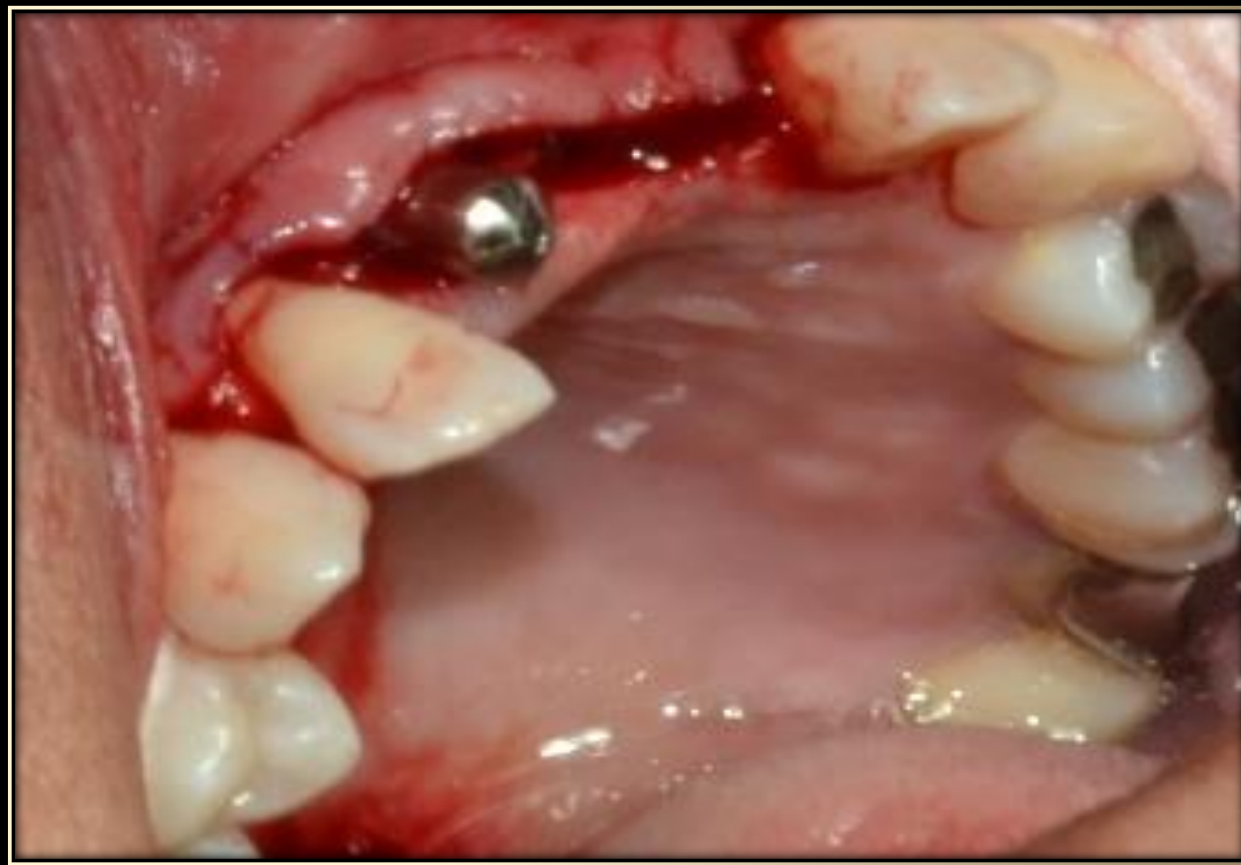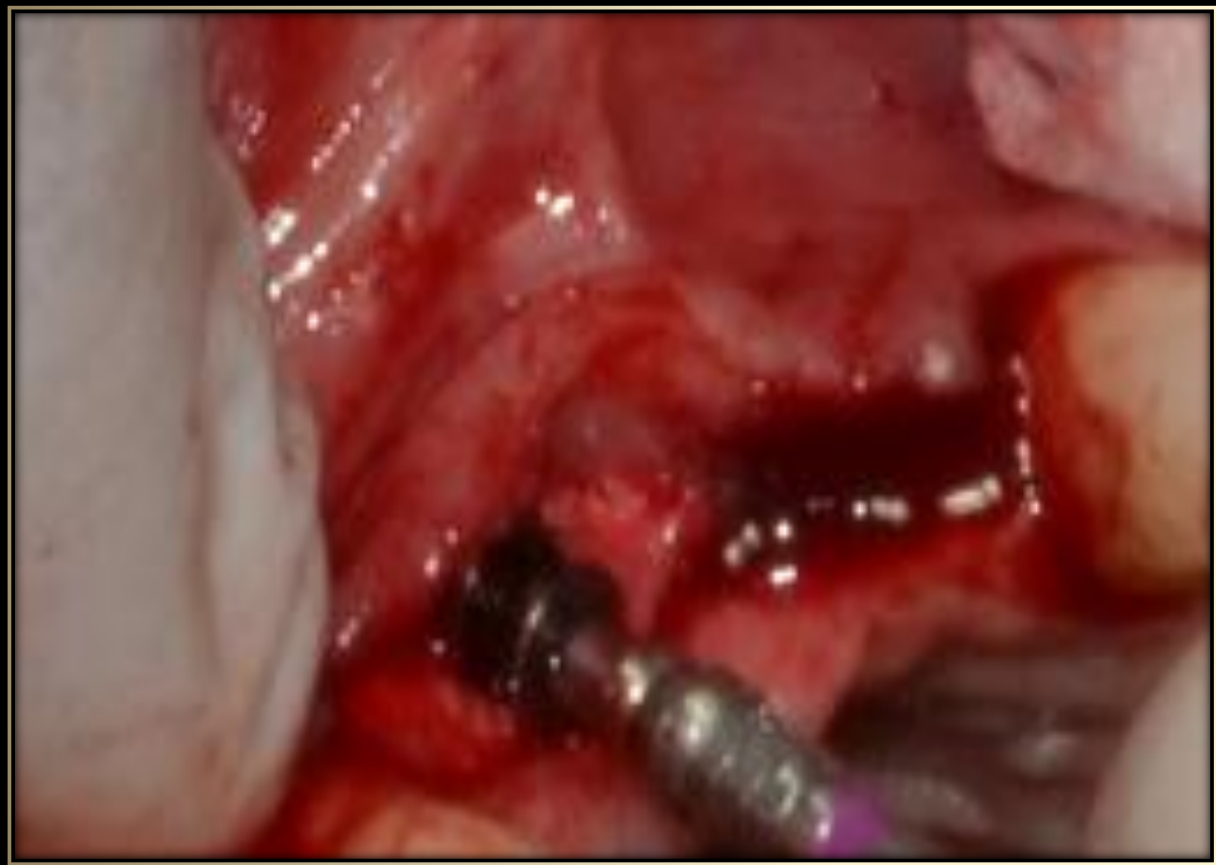Plan de tratamiento.

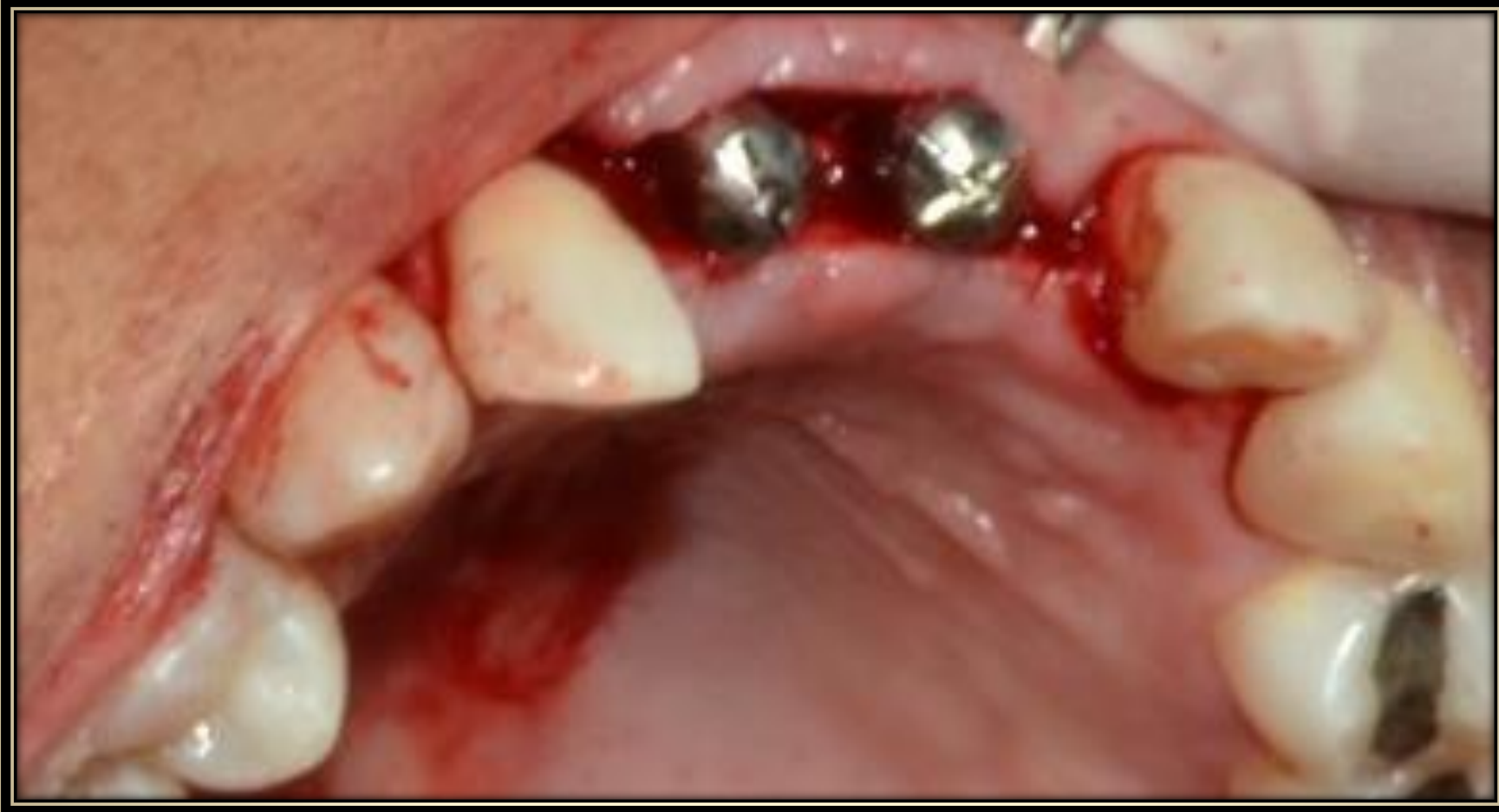

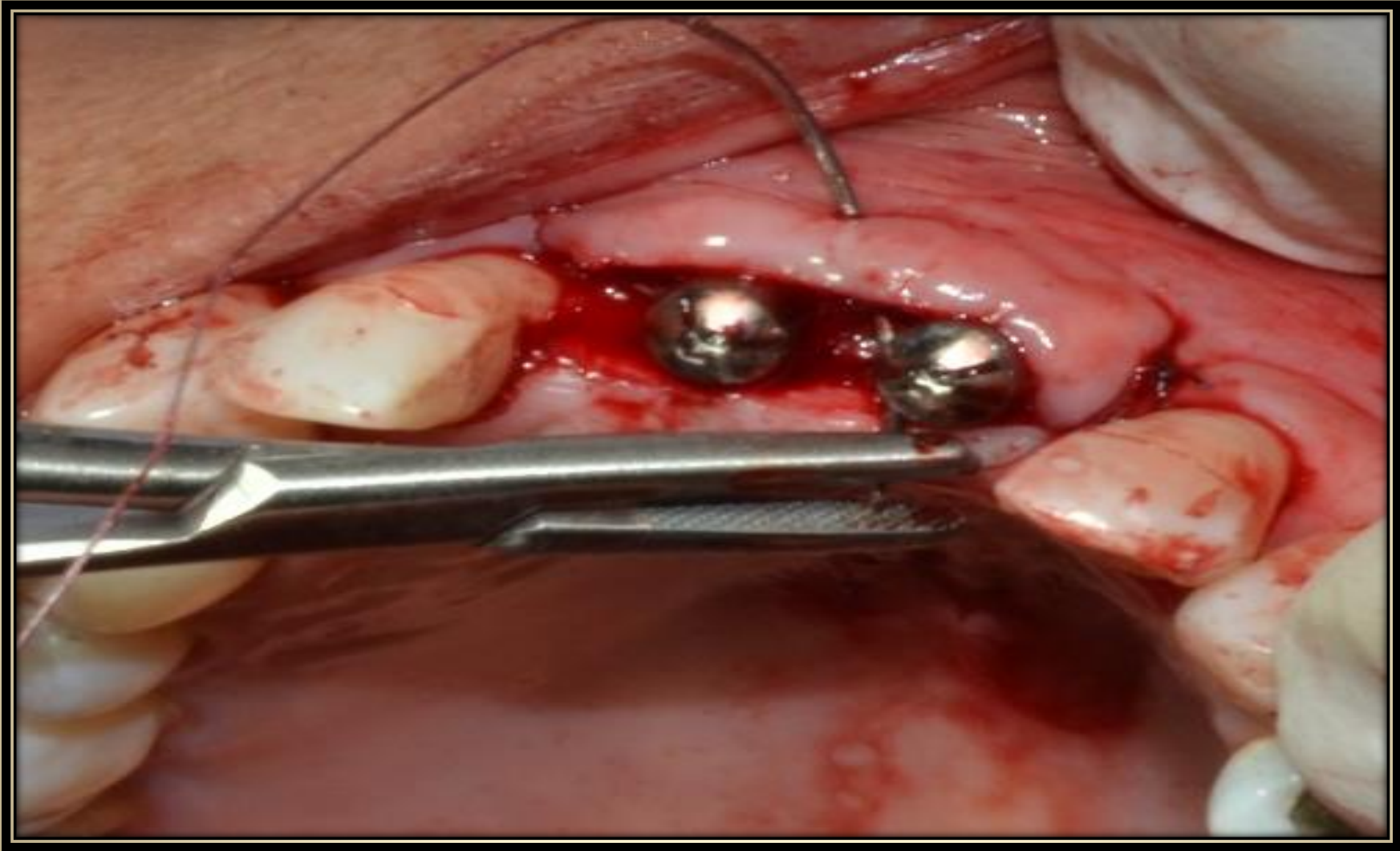COLOCACIÓN DE CICATRIZALES.

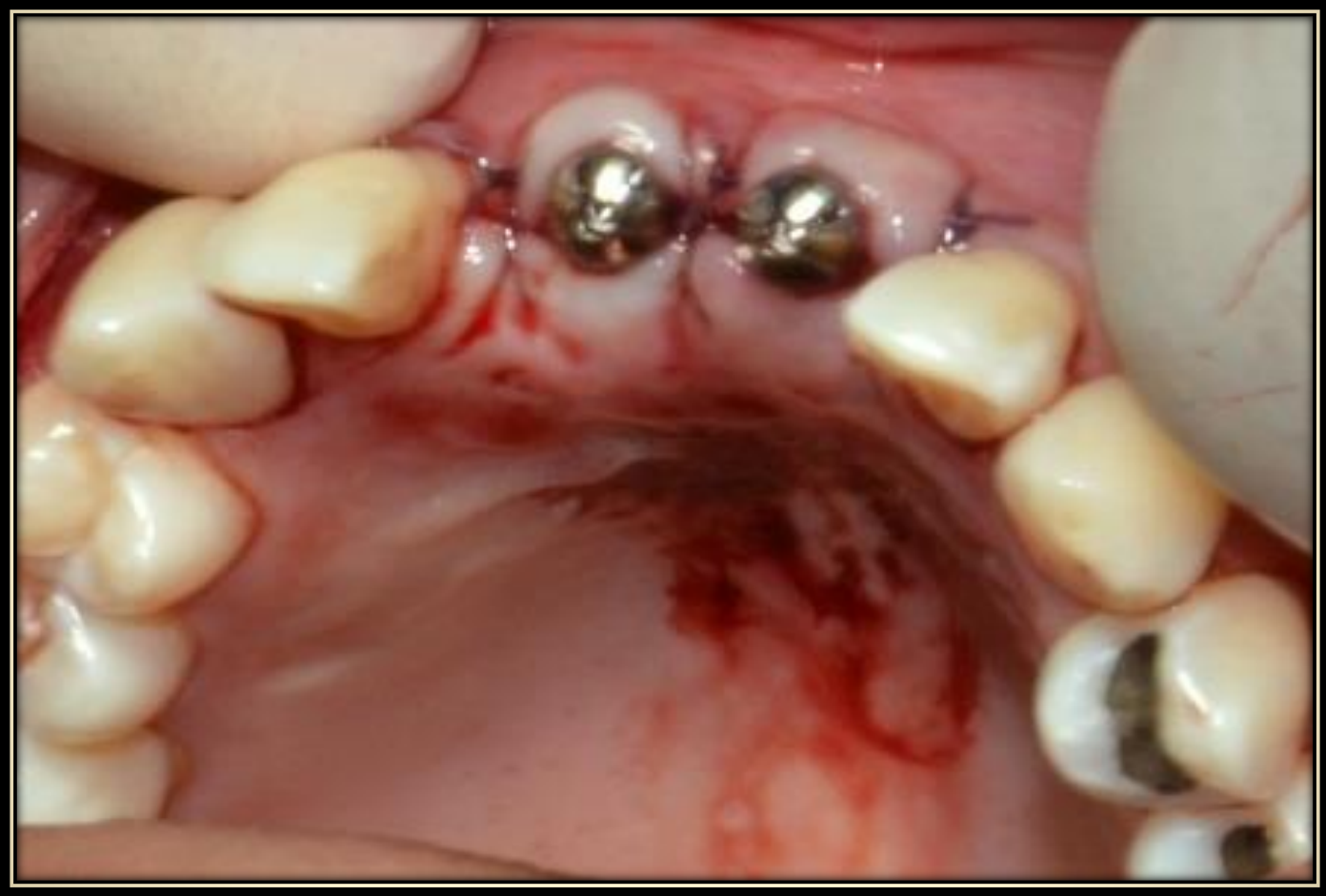

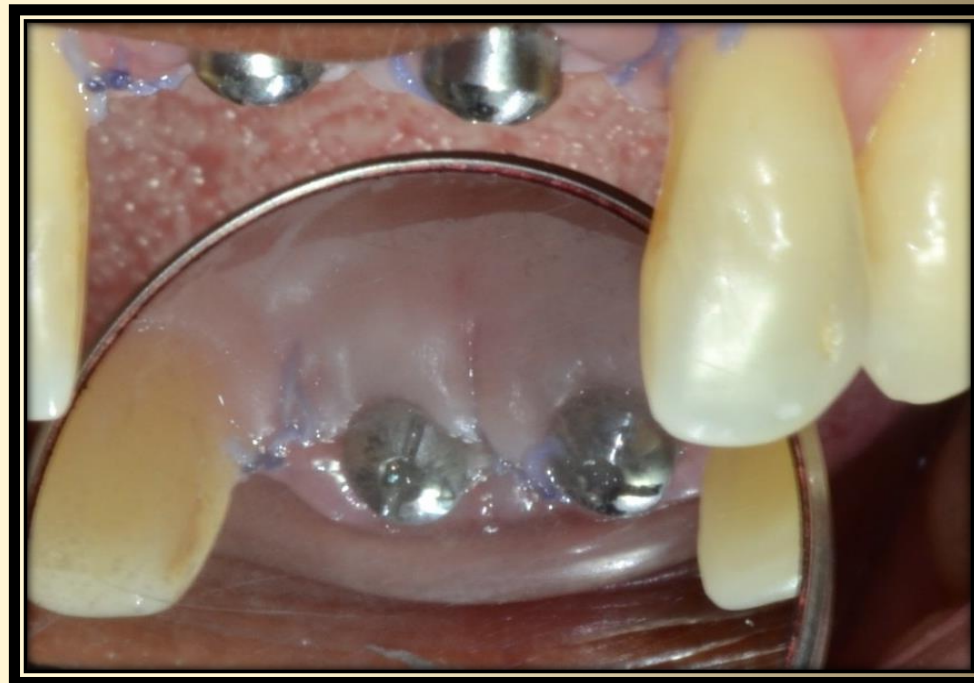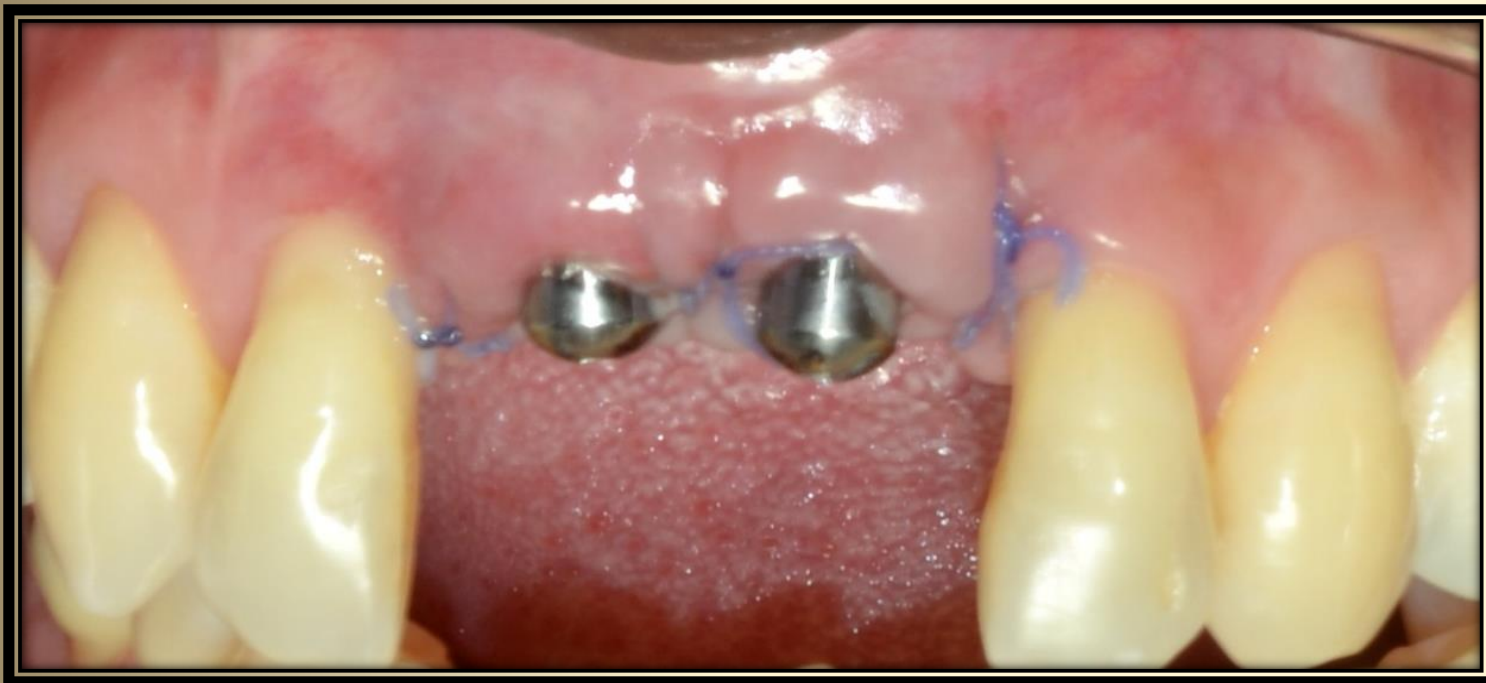






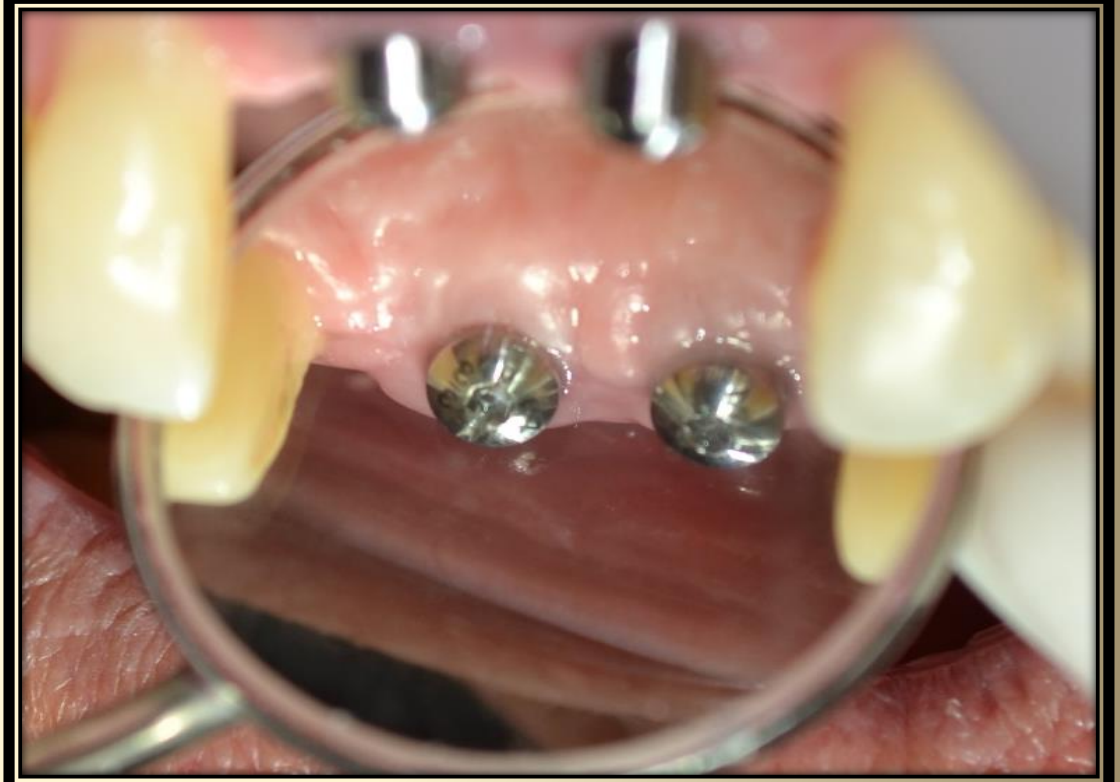
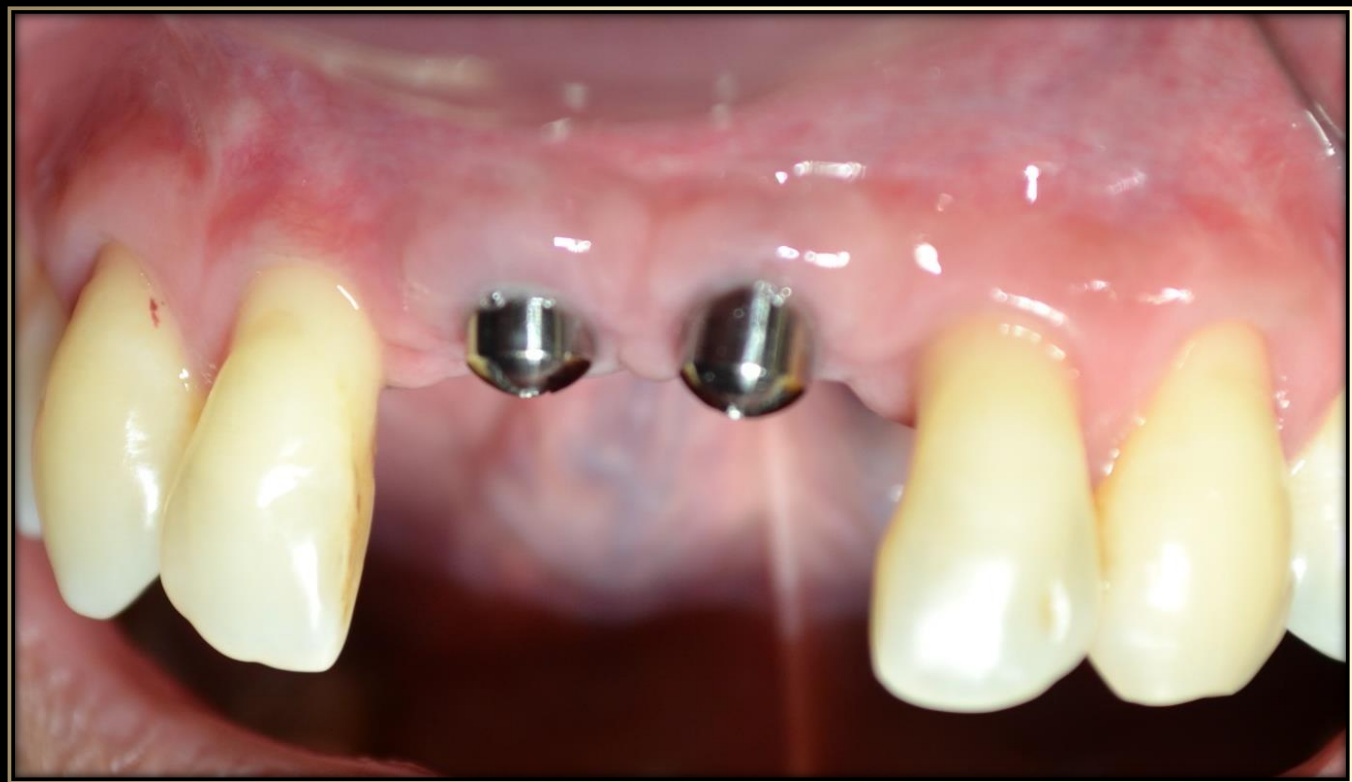




7 días.



20 días.

REGENERACIÓN ÓSEA GUIADA PERIIMPLANTAR.

Stefan Renvert
Ioannis Polyzois
Rory Maguire

Re-osseointegration on previously contaminated surfaces: a systematic review

Authors' Affiliations:

Stefan Renvert, Department of Health Sciences,
Kristianstad University, Sweden
Stefan Renvert, Ioannis Polyzois, Rory Maguire,
School of Dental Sciences, Trinity College, Dublin,
Ireland
Stefan Renvert, Blekinge Institute of Technology,
Karlskrona, Sweden

Correspondence to:

Dr Stefan Renvert
Department of Health Sciences
Kristianstad University
291 88 Kristianstad
Sweden
Tel.: +46 44 20 40 90
Fax: +46 44 12 85 90
e-mail: stefan.renvert@hkr.se

Conflicts of interest:

The authors declare no conflicts of interest.

Key words: animal studies, healing, peri-implantitis, re-osseointegration, treatment

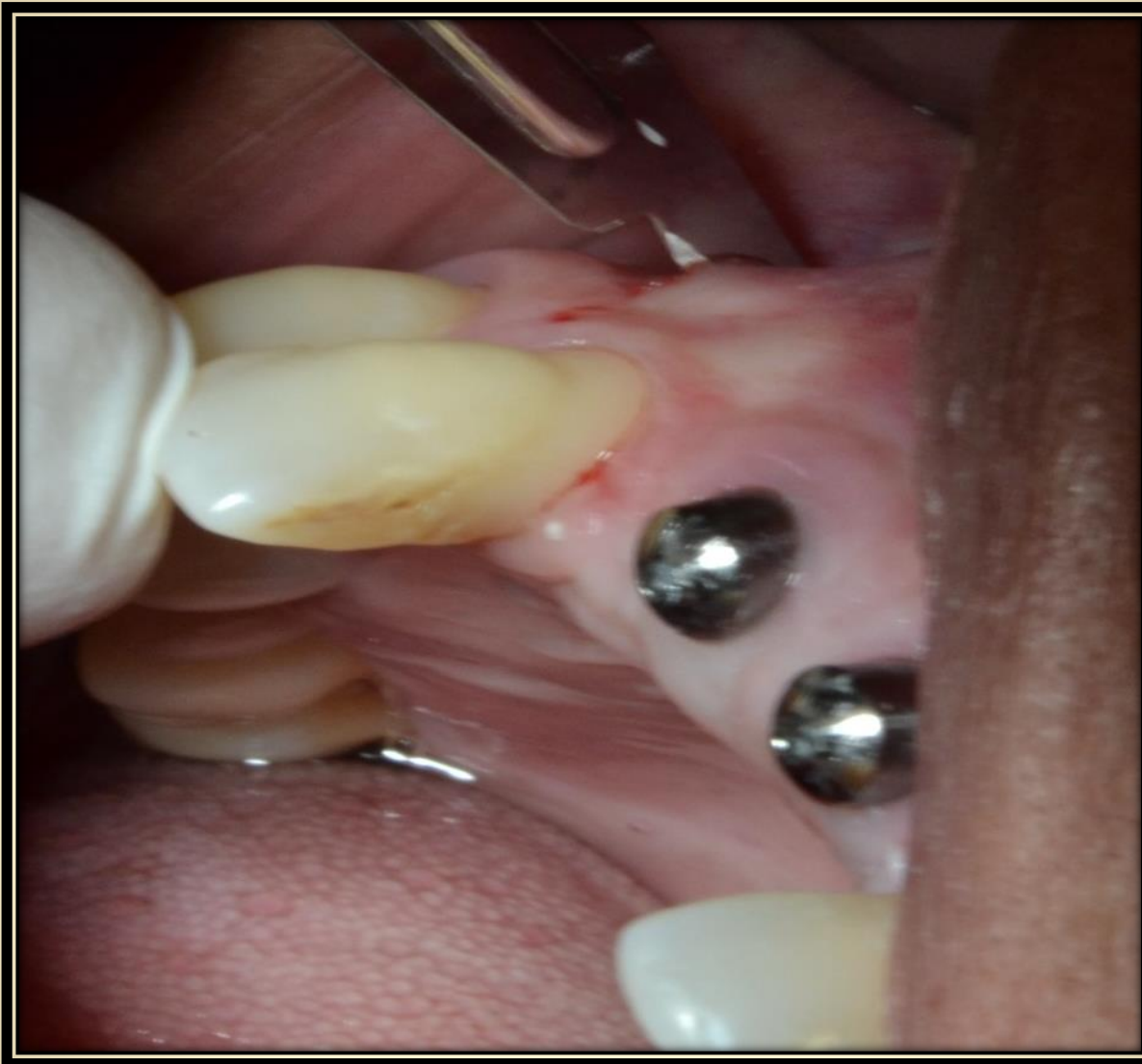Abstract

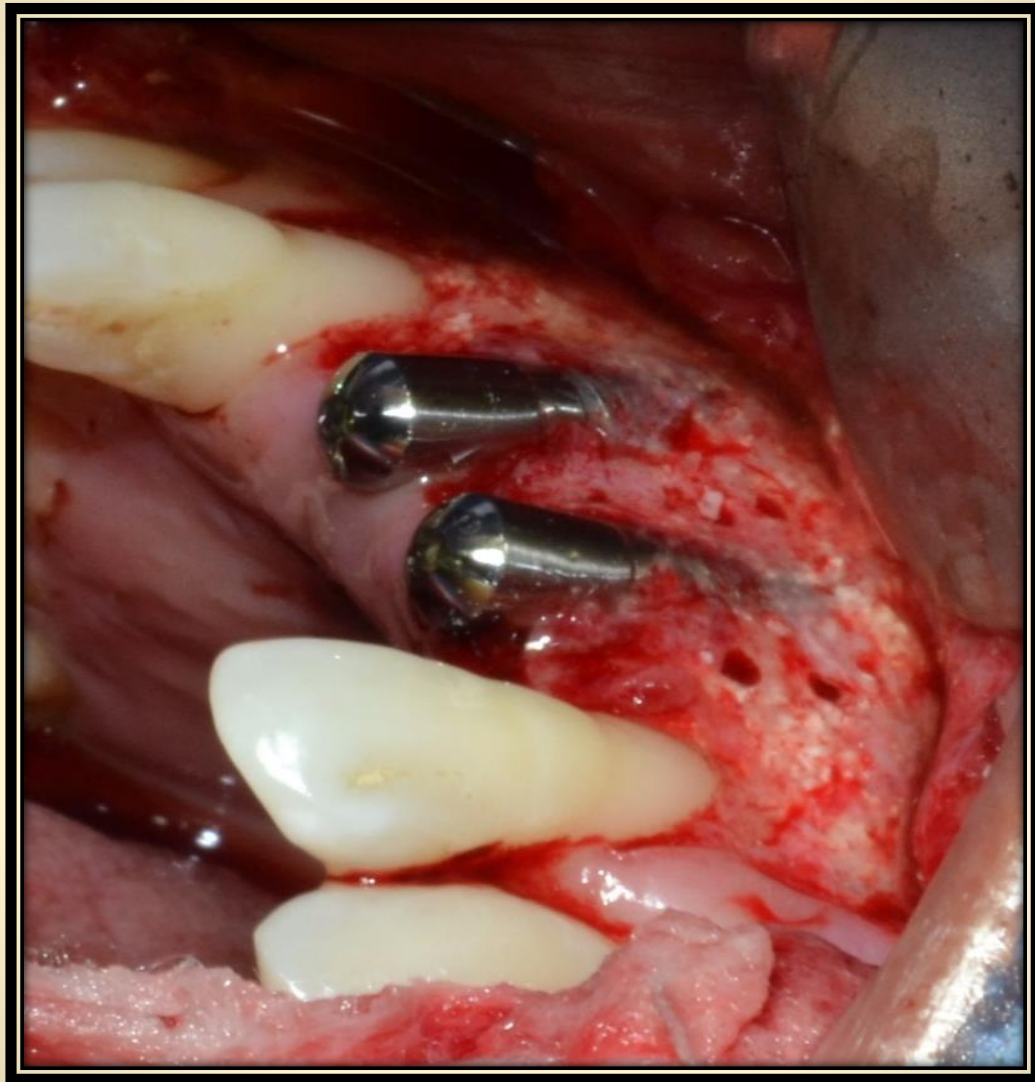
Objectives: The aim of this review was to search the literature for the existing evidence of re-osseointegration after treatment of peri-implantitis at contaminated implant surfaces.

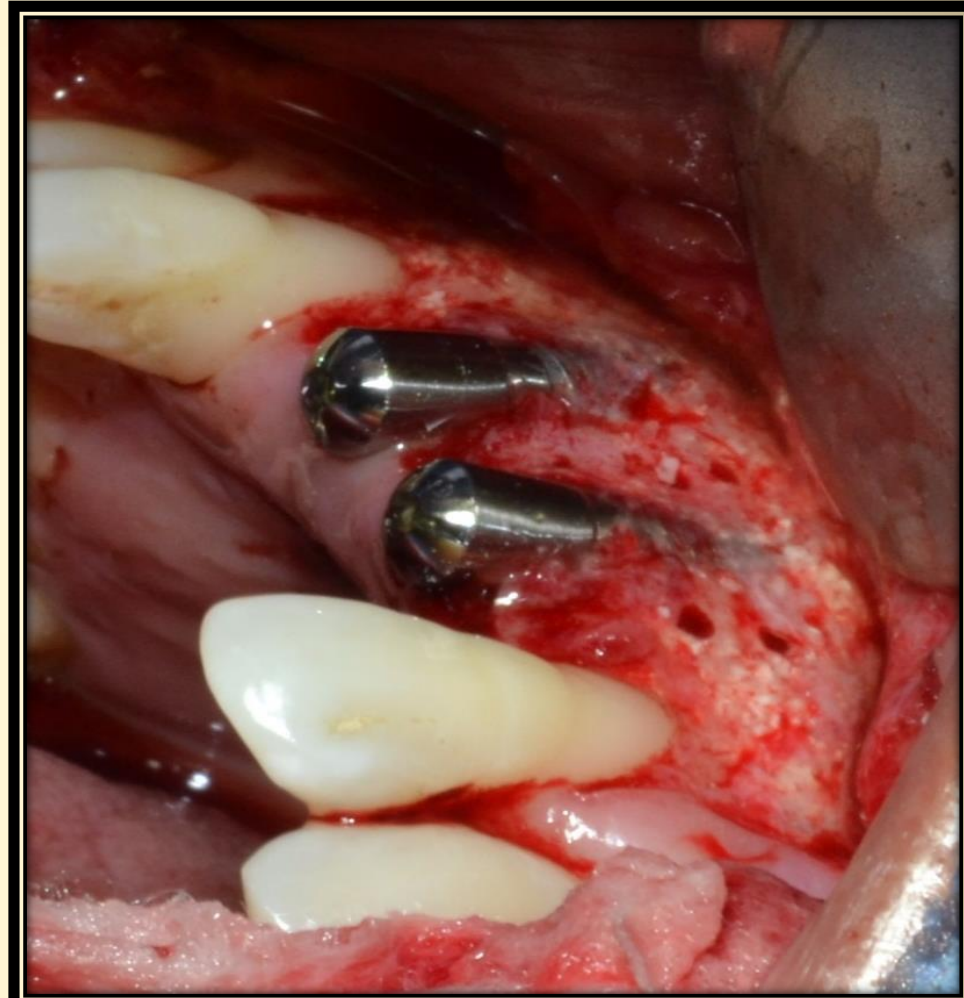
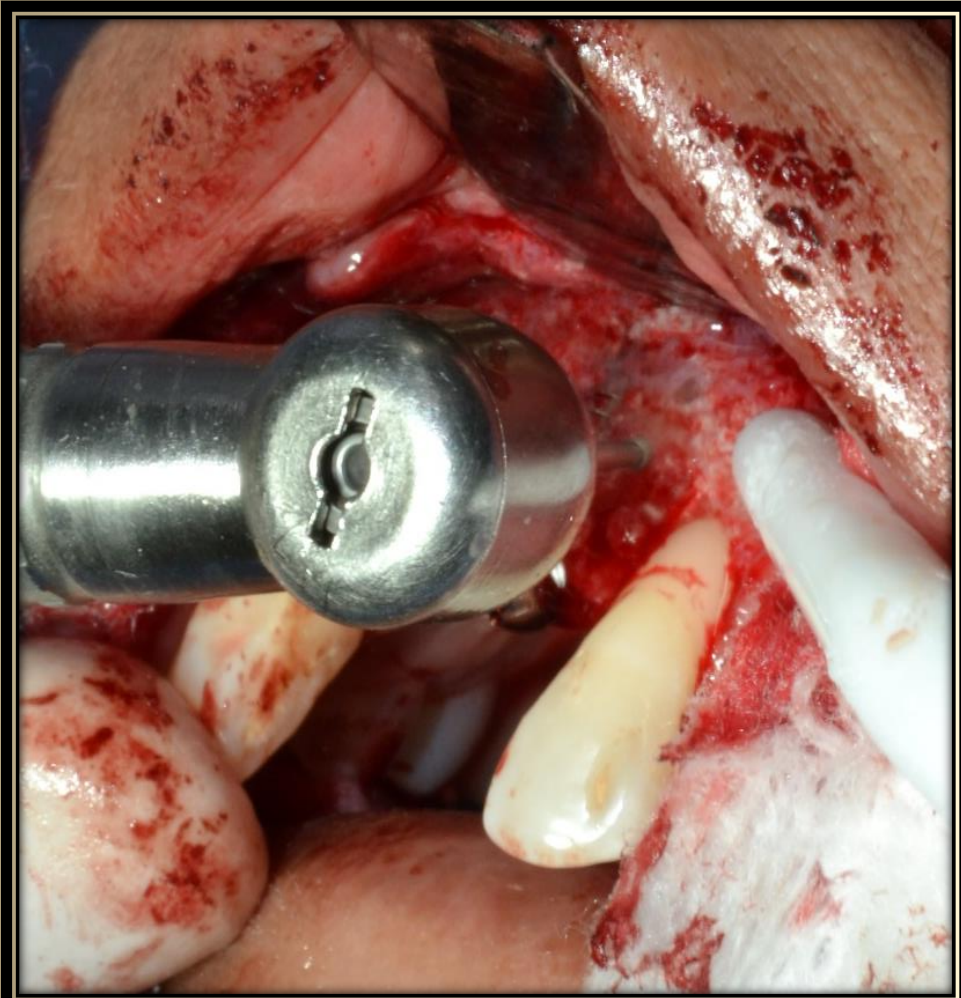
Material and Methods: A search of PubMed as well as additional hand search of articles were conducted. Publications and articles accepted for publication up to November 2008 were included.

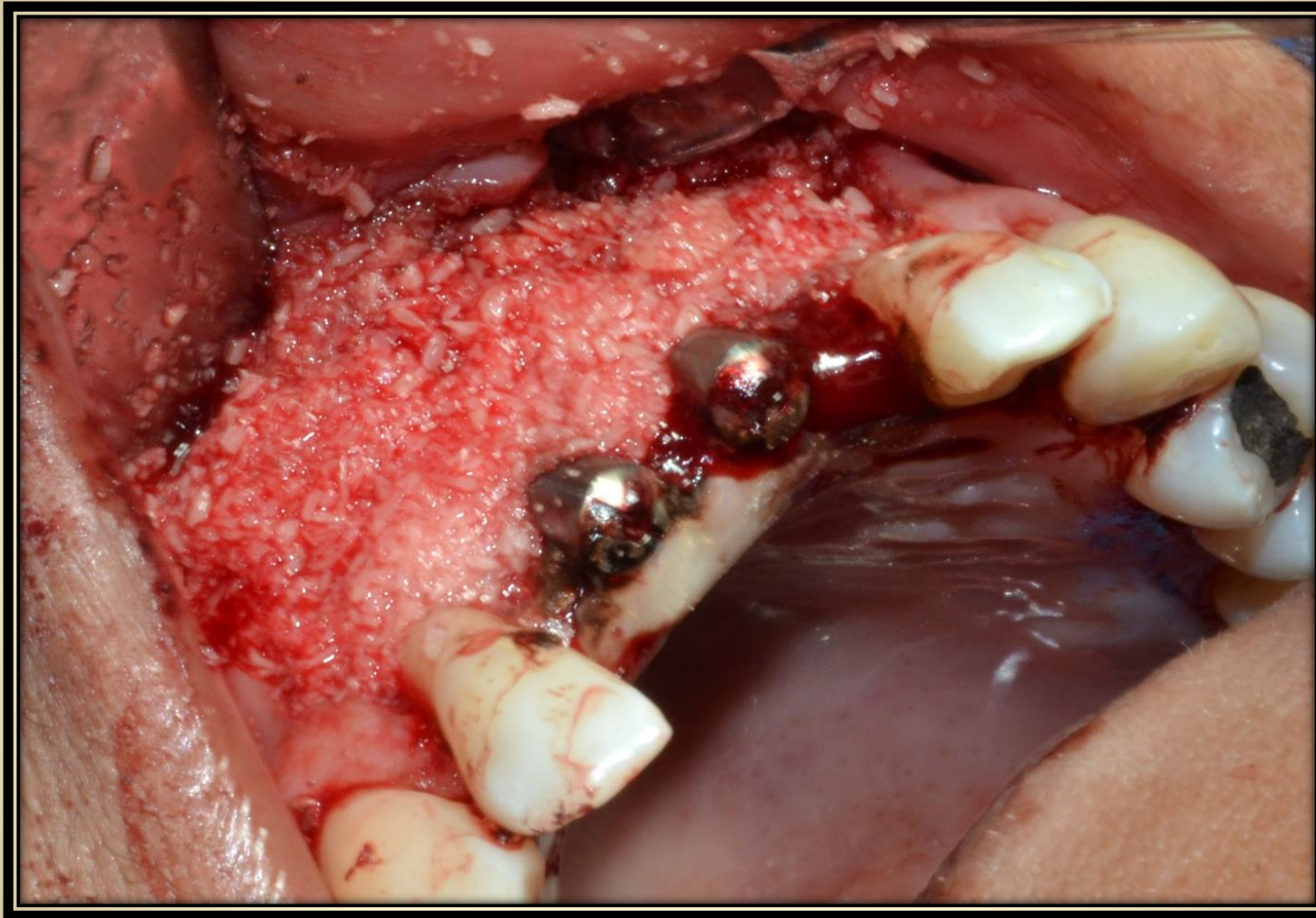
Results: A total of 25 animal studies fulfilled the inclusion criteria for this review. Access surgery with closed healing has been observed to positively influence the rate of re-osseointegration when compared with non-surgical decontamination of the implant surface with open healing. Open debridement including surface decontamination may result in re-osseointegration and this integration was more pronounced on rougher than on smooth implant surfaces. The adjunctive use of regenerative procedures resulted in varying amounts of re-osseointegration.

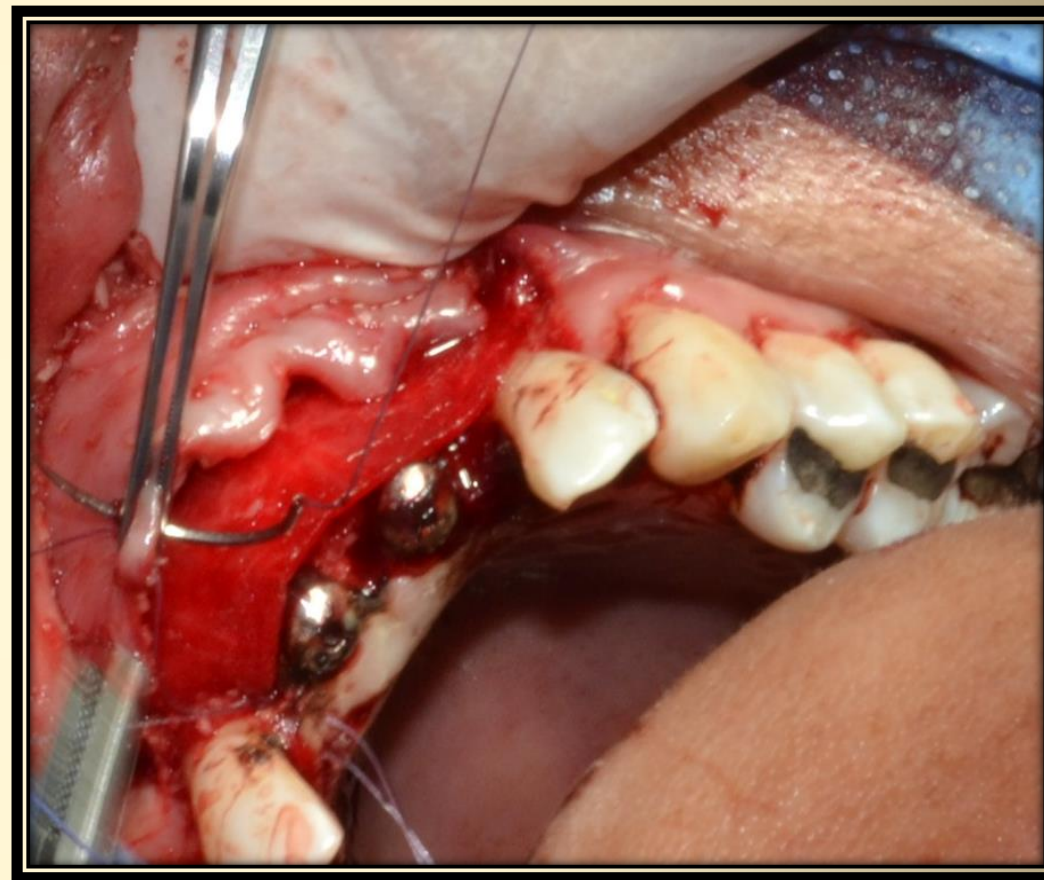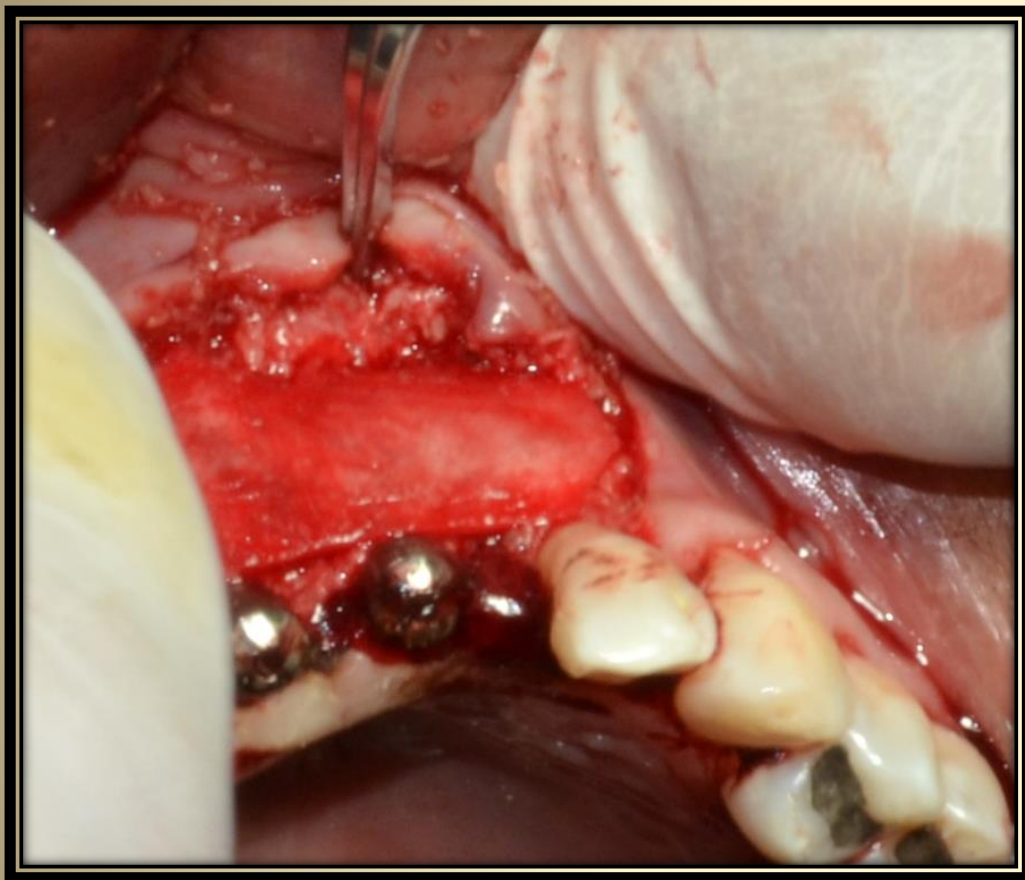
Conclusions: Re-osseointegration is possible to obtain on a previously contaminated implant surface and can occur in experimentally induced peri-implantitis defects following therapy. The amount of re-osseointegration, varied considerably within and between studies. Implant surface characteristics may influence the degree of re-osseointegration. Surface decontamination alone can not achieve substantial re-osseointegration on a previously contaminated implant surface. No method predictably accomplished complete resolution of the peri-implant defect.

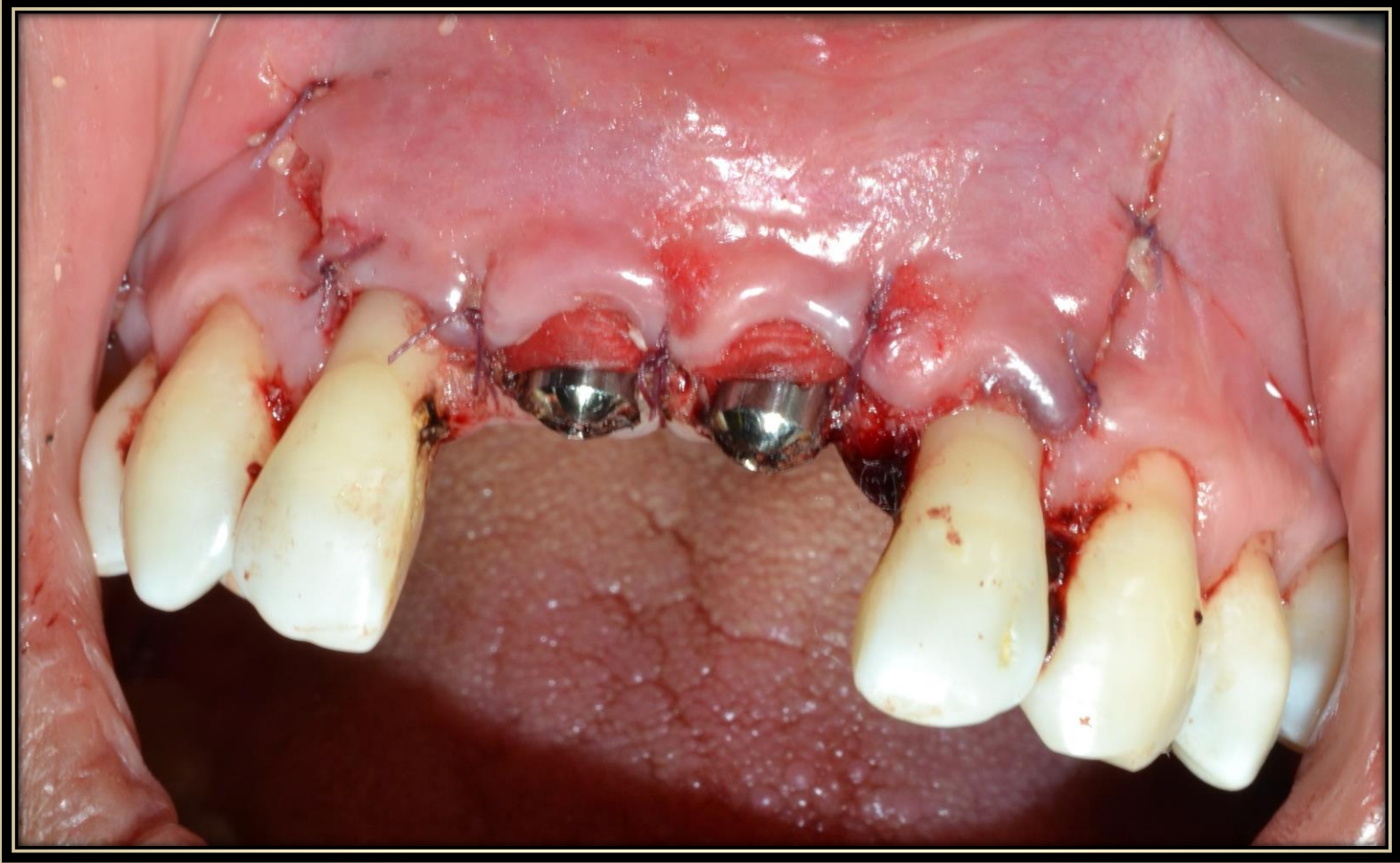


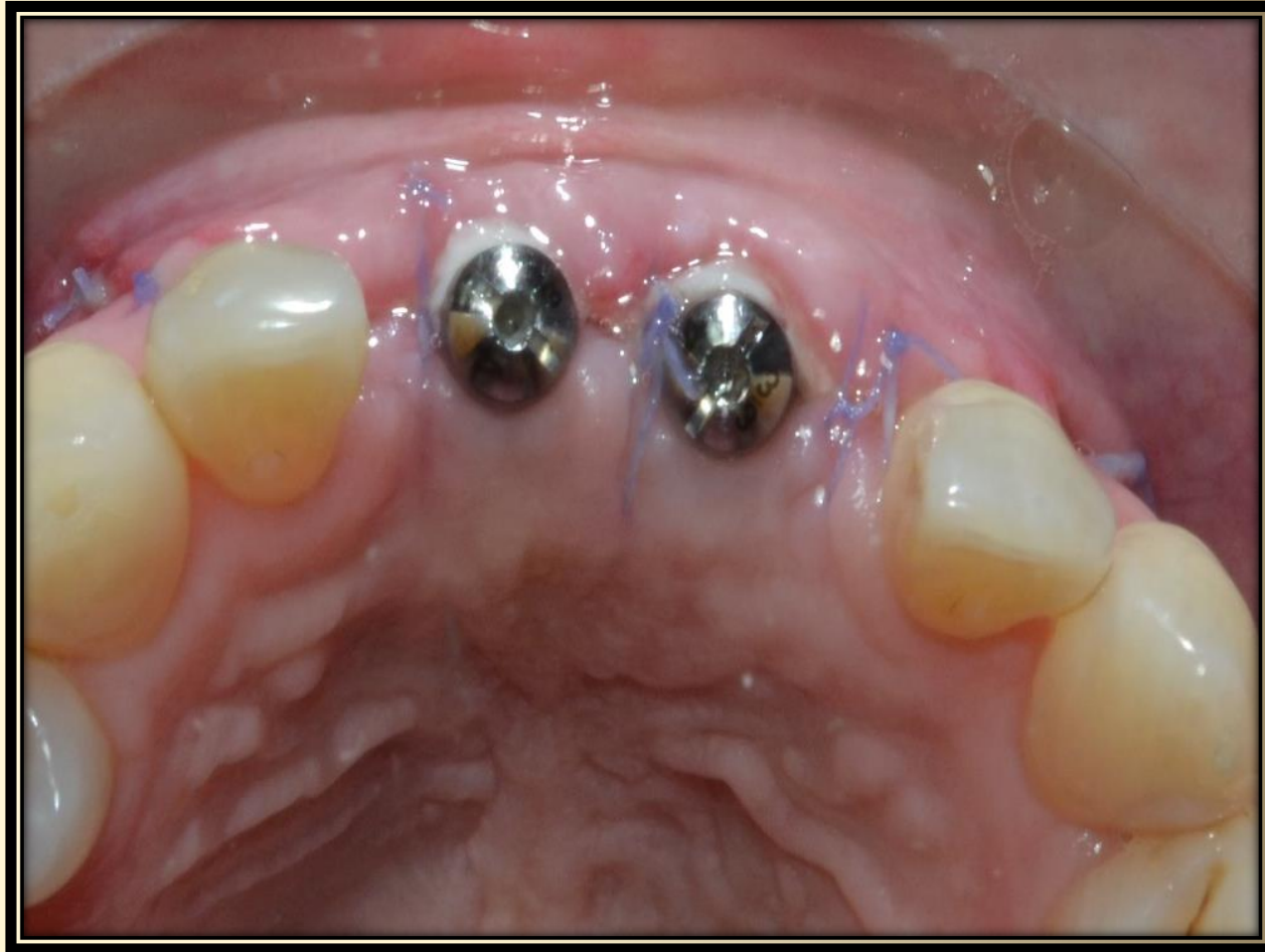
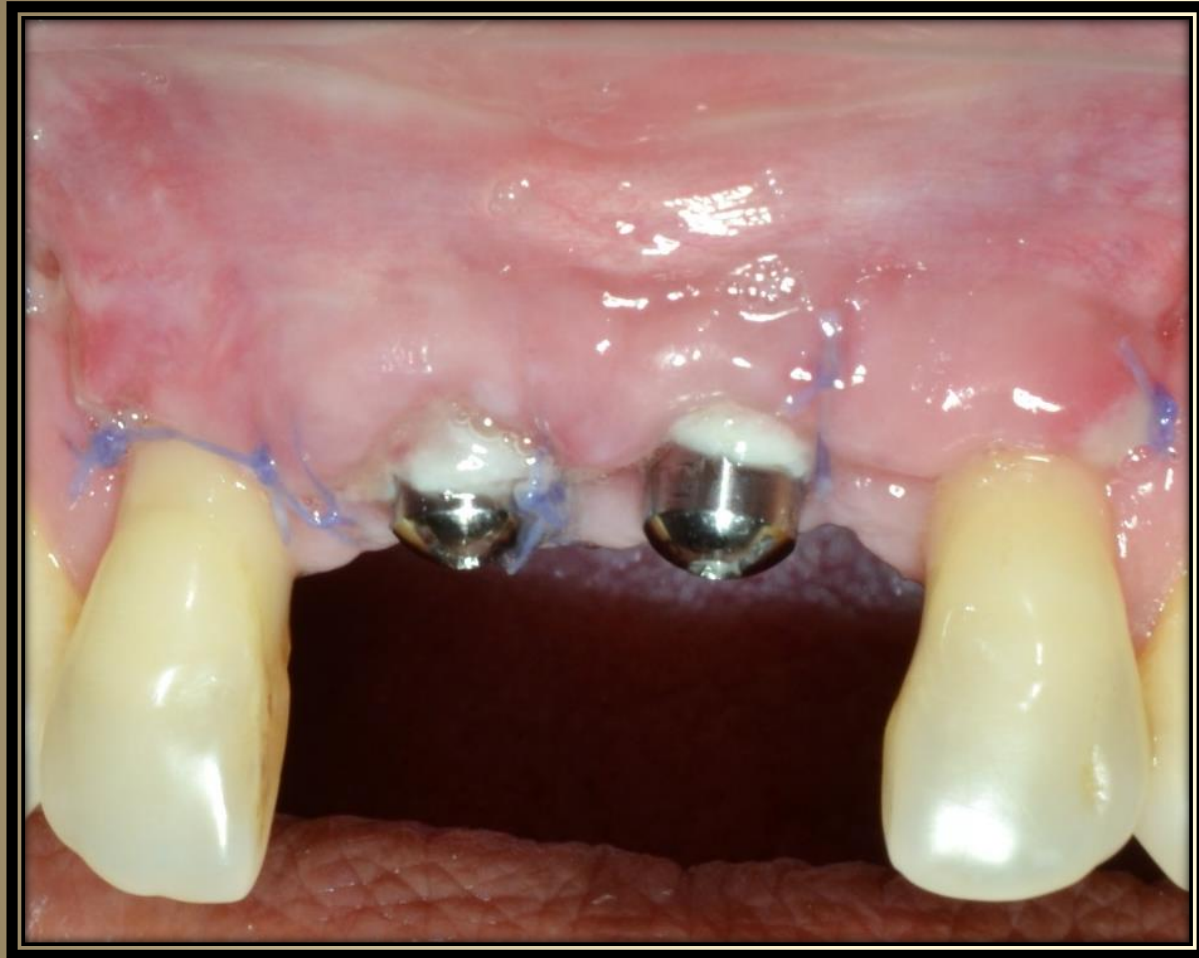









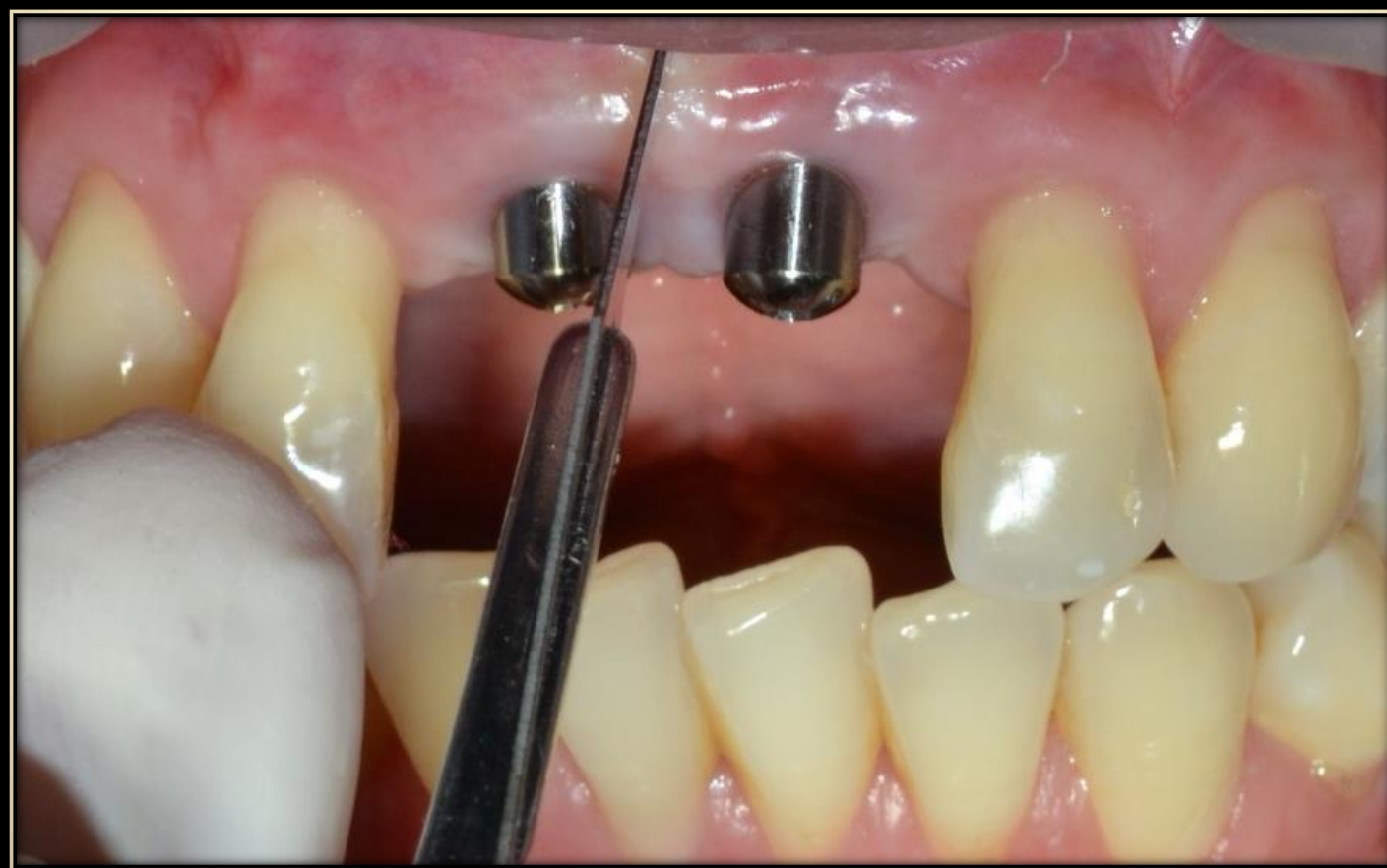7 días.

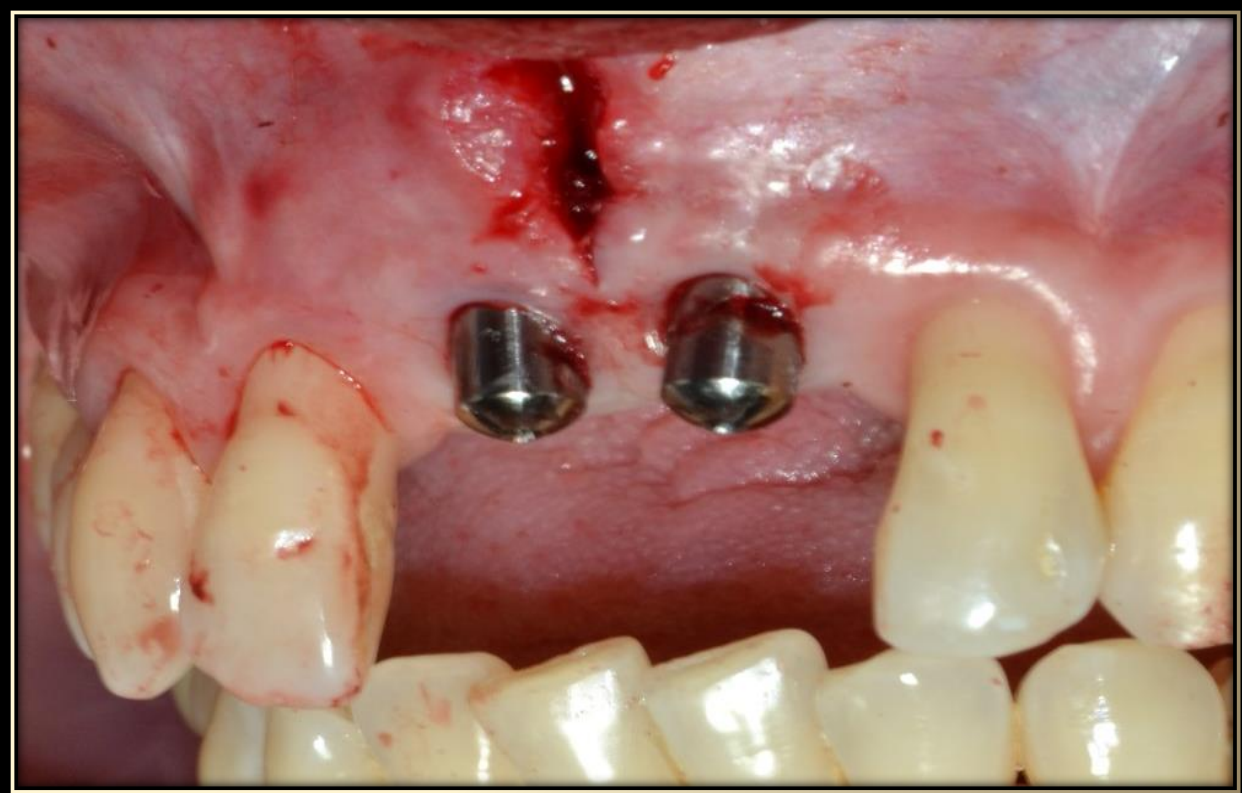
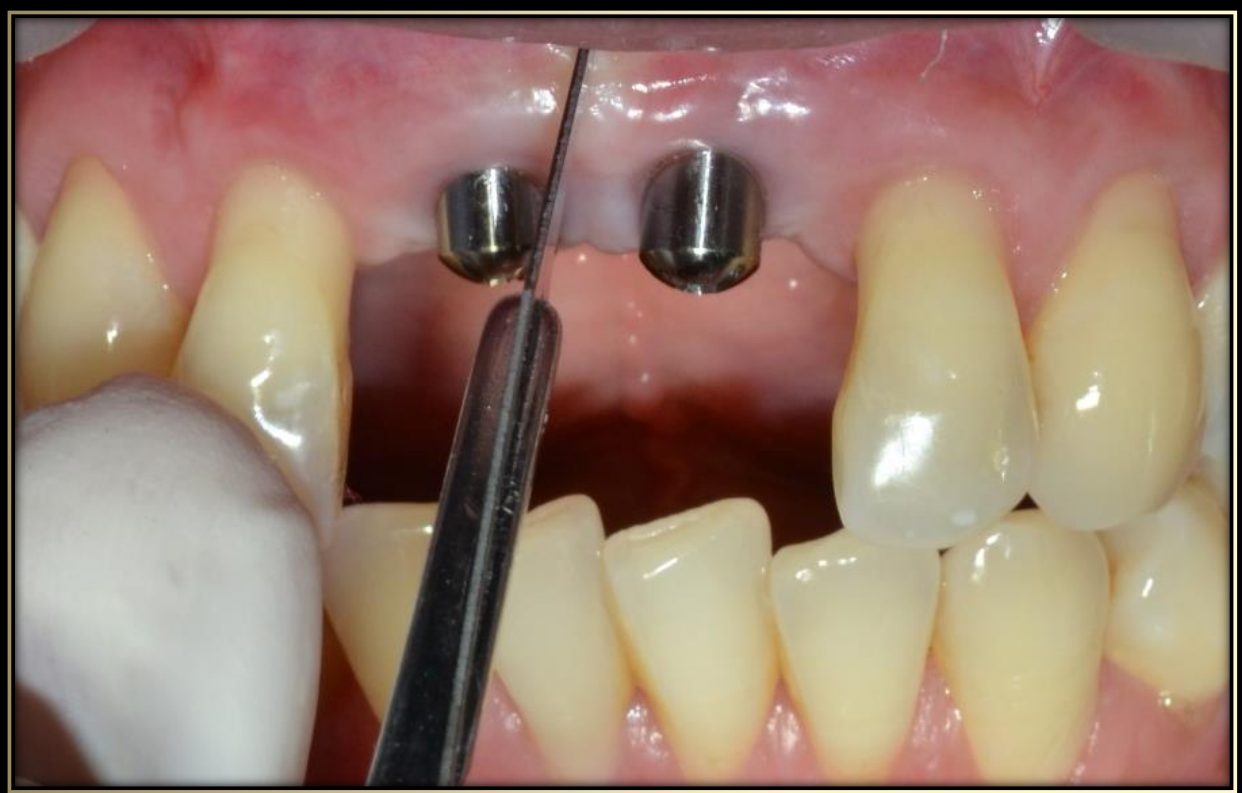AUMENTO DE ENCÍA INSERTADA.

Int J Oral Maxillofac Implants. 2009 Jul-Aug;24(4):712-9.

The influence of soft tissue thickness on crestal bone changes around implants: a 1-year prospective controlled clinical trial.

Linkevicius T¹, Apse P, Grybauskas S, Puisys A.





RECONSTRUCTIVE

Fascia Lata Allografts as Biological Mesh in Abdominal Wall Repair: Preliminary Outcomes from a Retrospective Case Series

Cesare Tiengo, M.D.
Giorgio Giasidis, M.D.
Bruno Azzena, M.D.

Padova, Italy


Background: The use of biological meshes in management of infected abdominal hernias or in abdominal fields at high risk of infection (potentially contaminated or with relevant comorbidities) is well established. Available products include xenogenic patches or decellularized dermal allografts. Despite their biomechanical features, banked fascial allografts have not been investigated yet in this setting. The authors evaluated the safety and effectiveness of banked fascia lata allografts as biological meshes in abdominal wall repair.

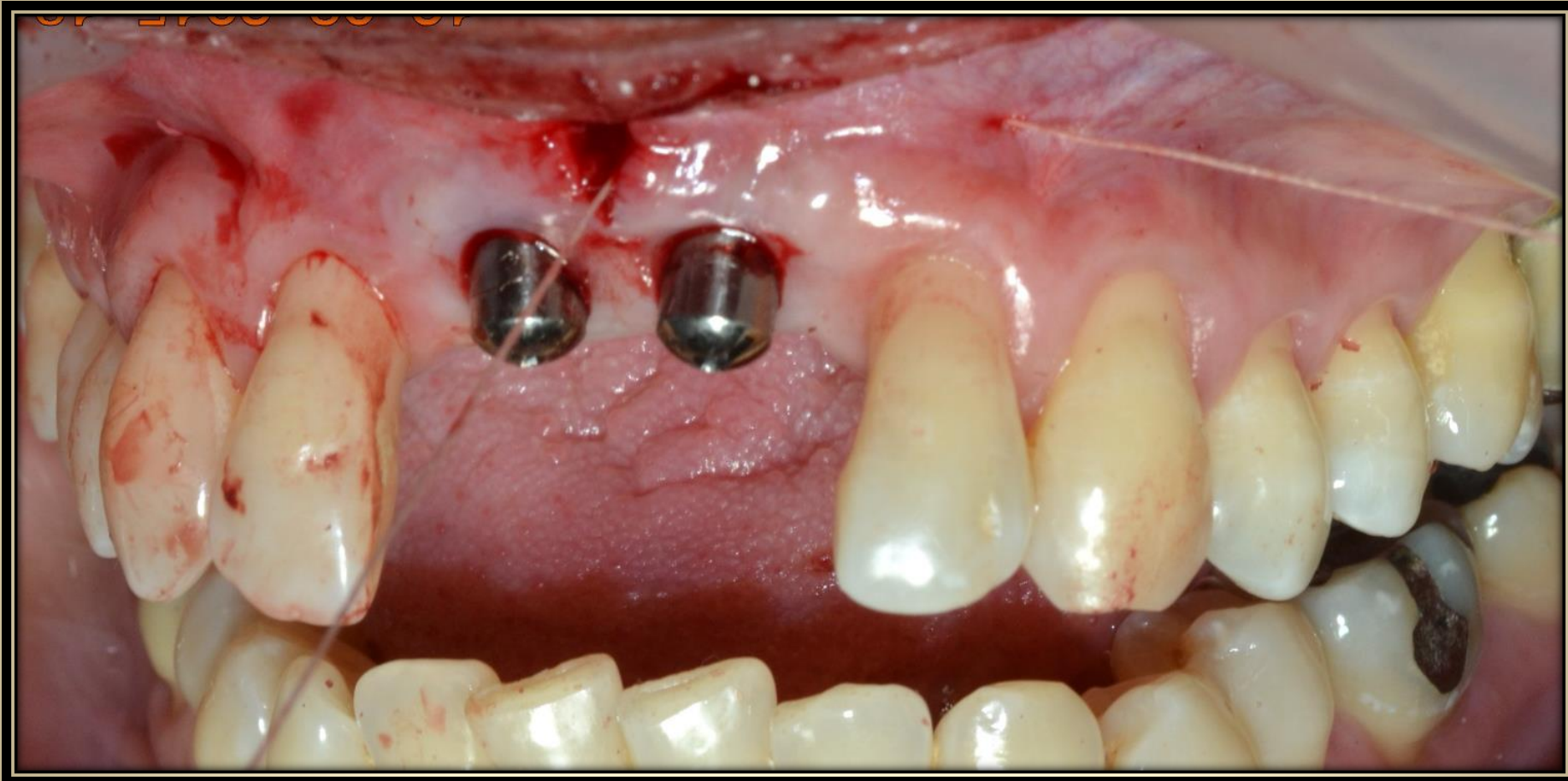
Methods: A consecutive series of patients affected by abdominal wall defects and who were candidates for repair by means of a biological mesh and treated in the authors' institution with banked fascia lata allografts were reviewed retrospectively. Data from clinical and instrumental follow-up evaluations up to 48 months (average, 23 months) were analyzed.

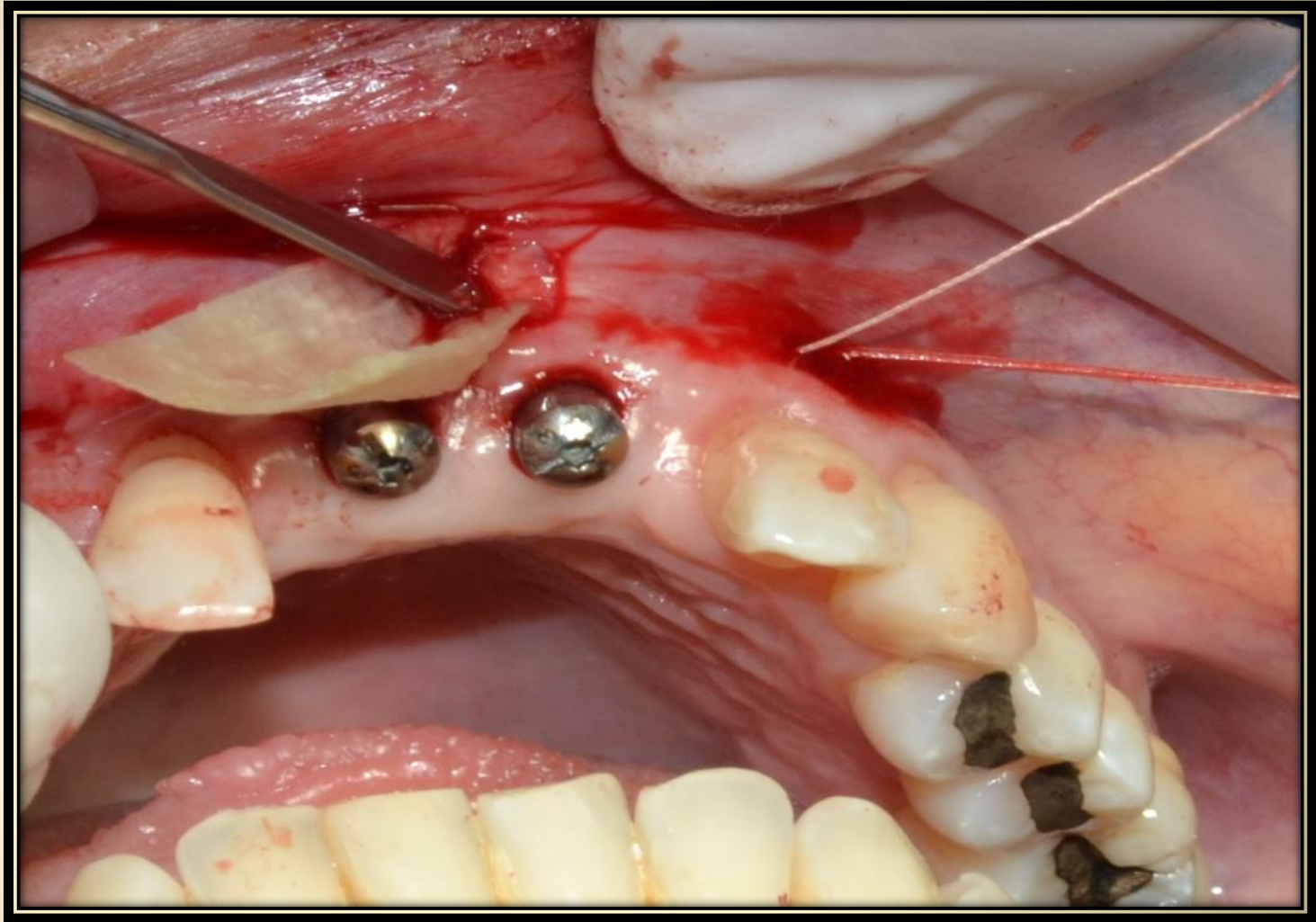
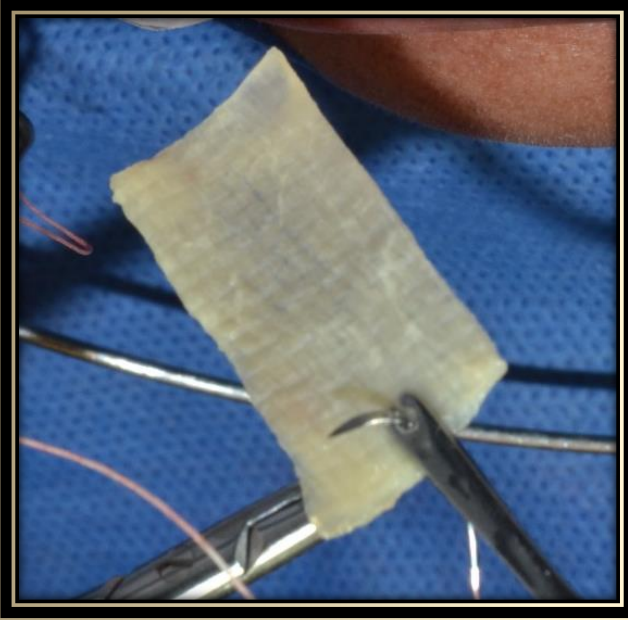
Results: Twenty-one patients (aged 1 to 86 years) with abdominal wall defects resulting from traumatic ($n = 1$), neoplastic ($n = 6$), or multiple previous laparotomies ($n = 14$) were treated from January of 2008 to October of 2012. Operations had no relevant postoperative complications. At clinical/instrumental follow-up examinations, no major signs of recurrence, laxity, infection of grafts, or other related pathologic symptoms were recorded. Three patients suffered from temporary minor complications (e.g., wound seroma, partial cutaneous dehiscence). At instrumental (computed tomographic scan or magnetic resonance imaging) evaluations, the neofascial tissue appeared stable until medium-term follow-up (3 to 6 months), later being gradually degraded and apparently replaced by host tissue.

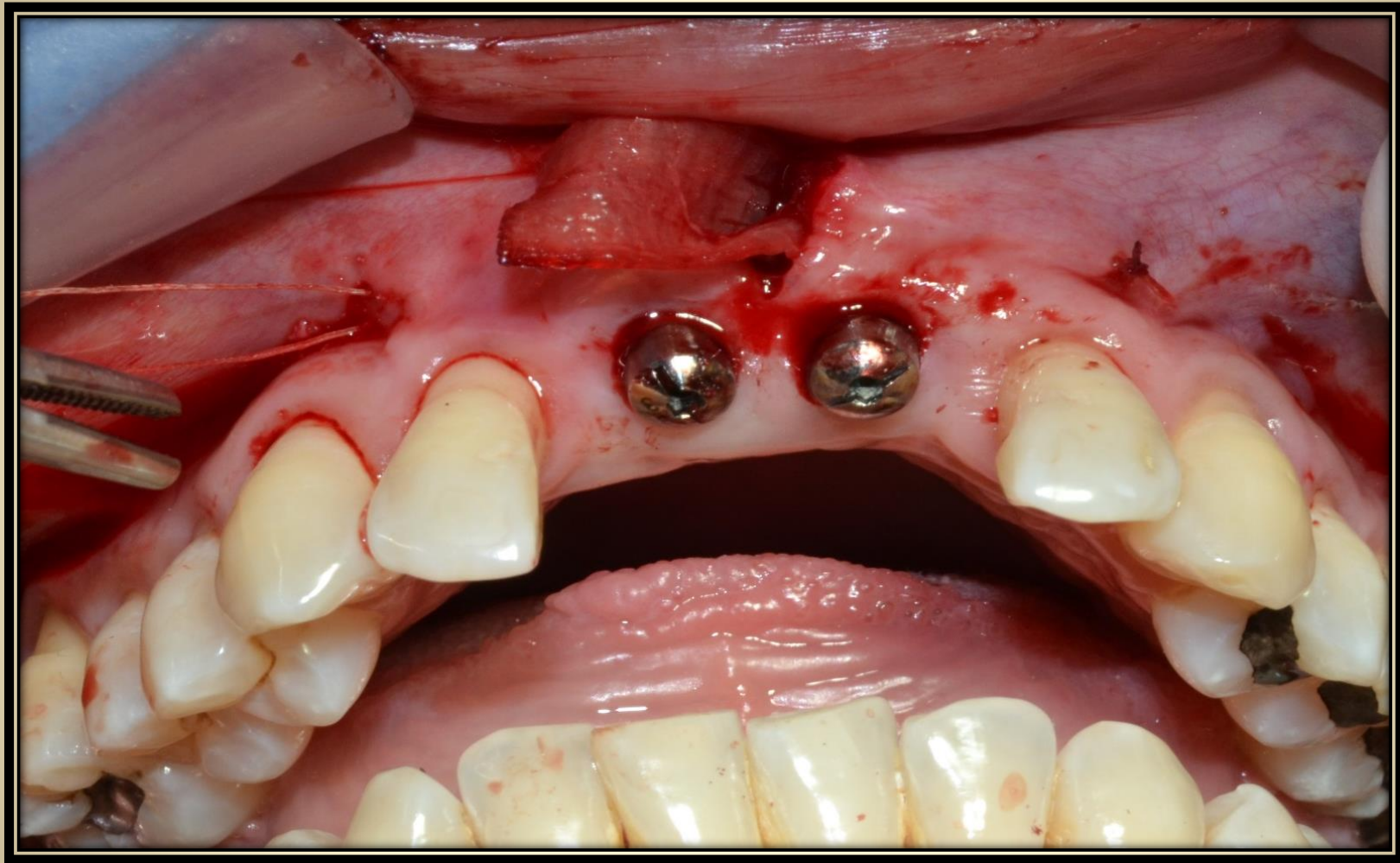
Conclusion: According to limited preliminary outcomes, banked fascia lata allografts seem to provide a biocompatible, safe, and effective alternative to other biological meshes. (*Plast. Reconstr. Surg.* 132: 631e, 2013.)

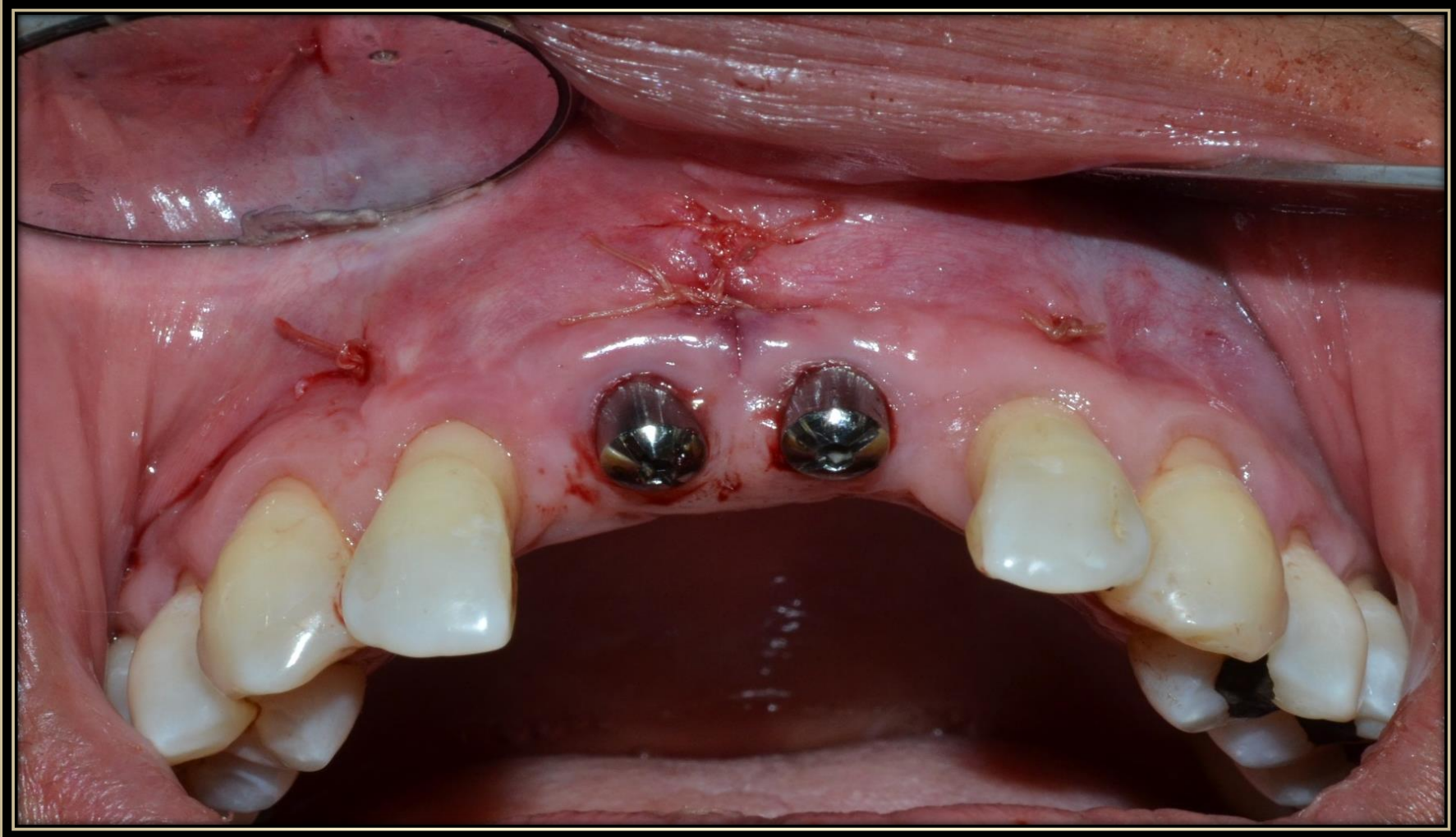
CLINICAL QUESTION/LEVEL OF EVIDENCE: Therapeutic, IV.

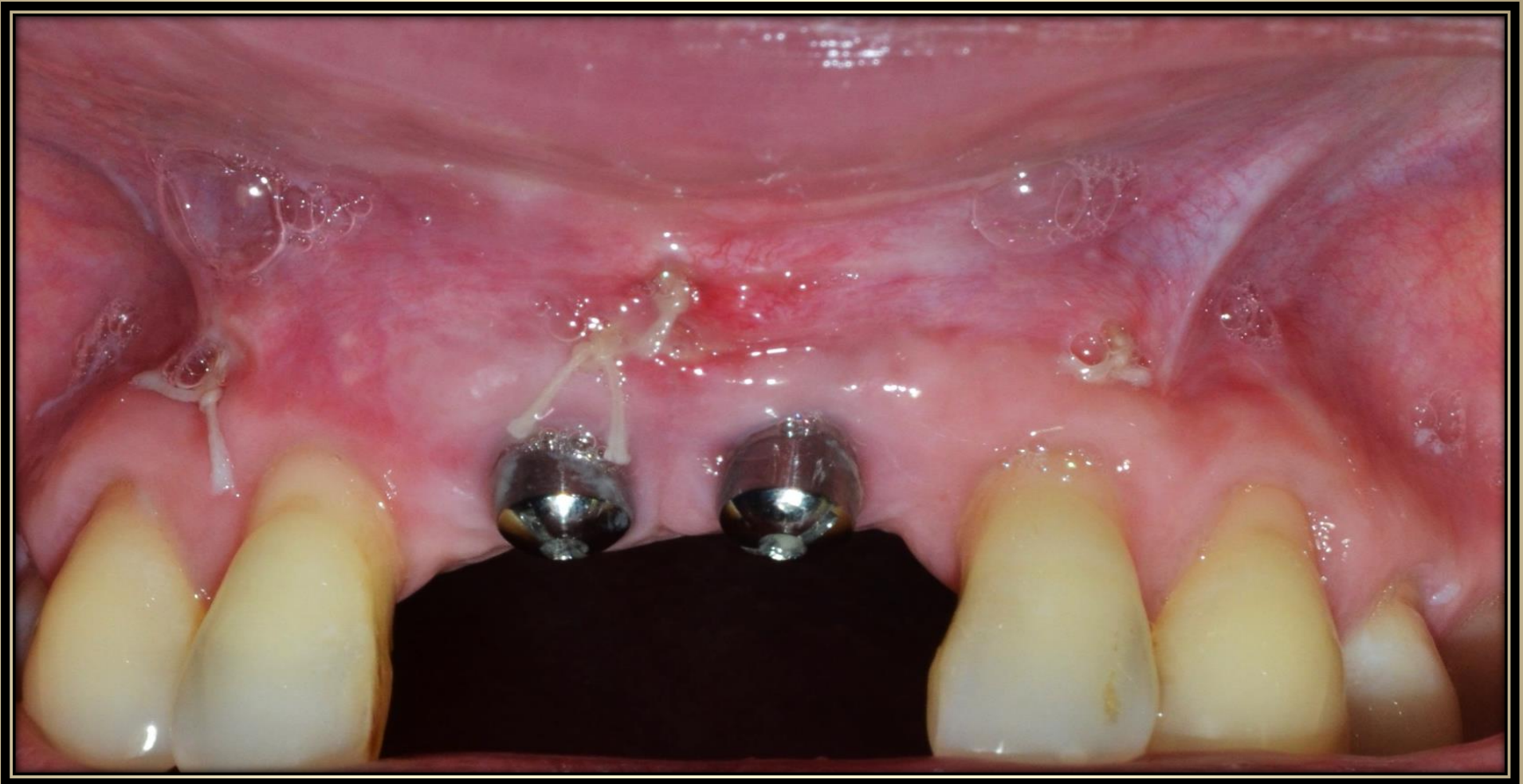




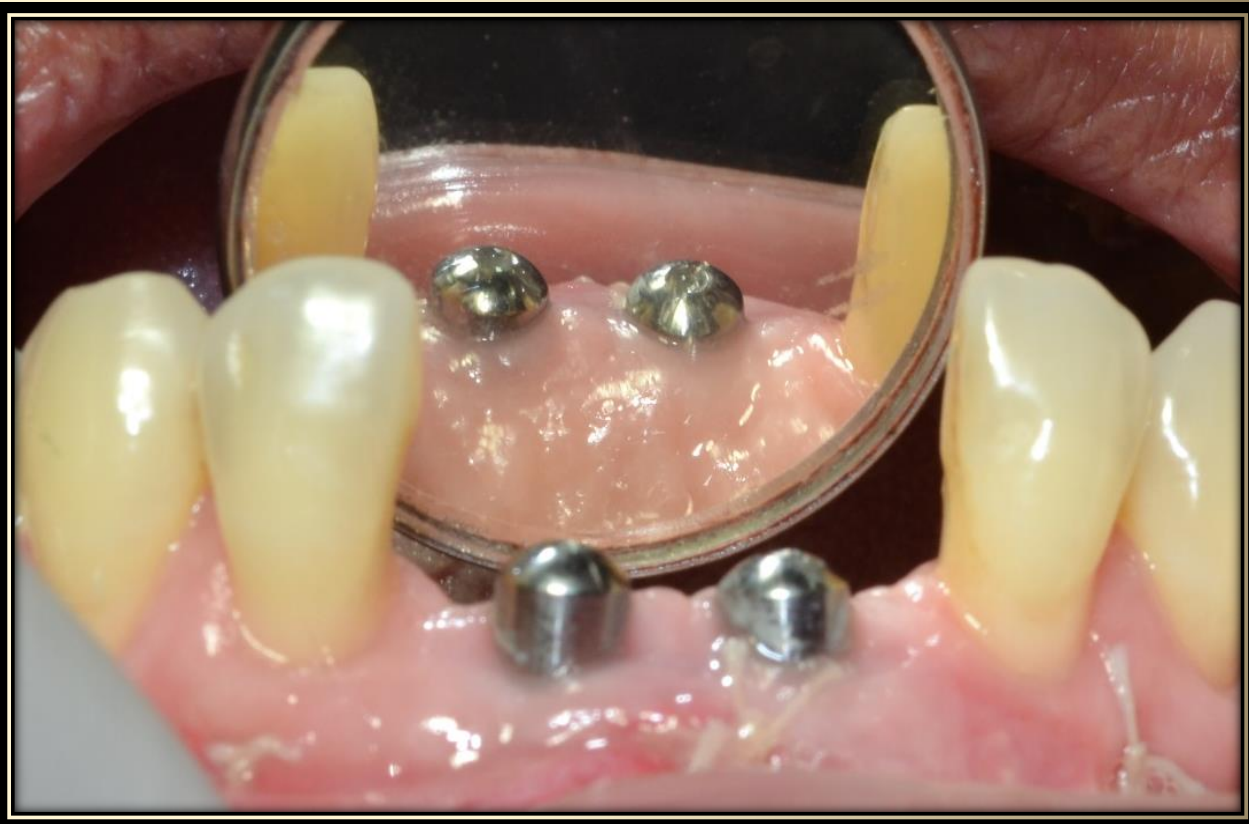
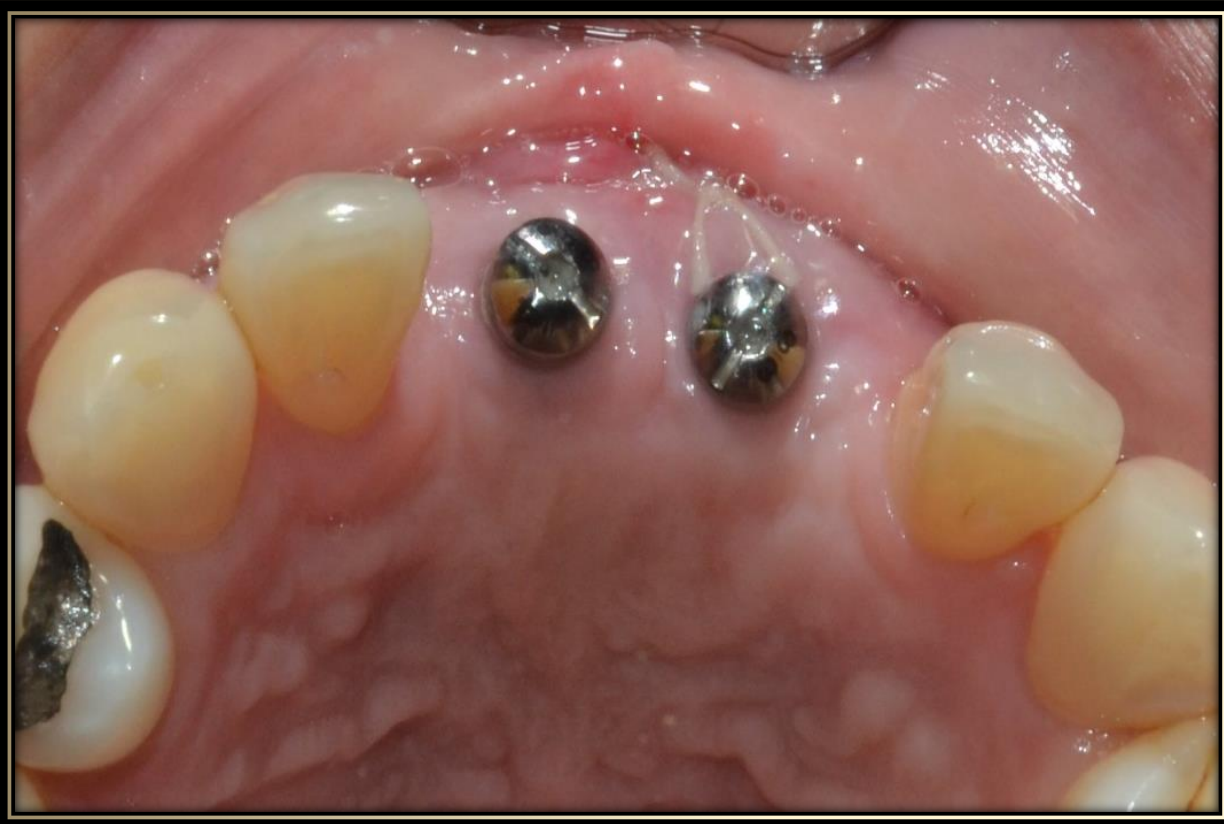





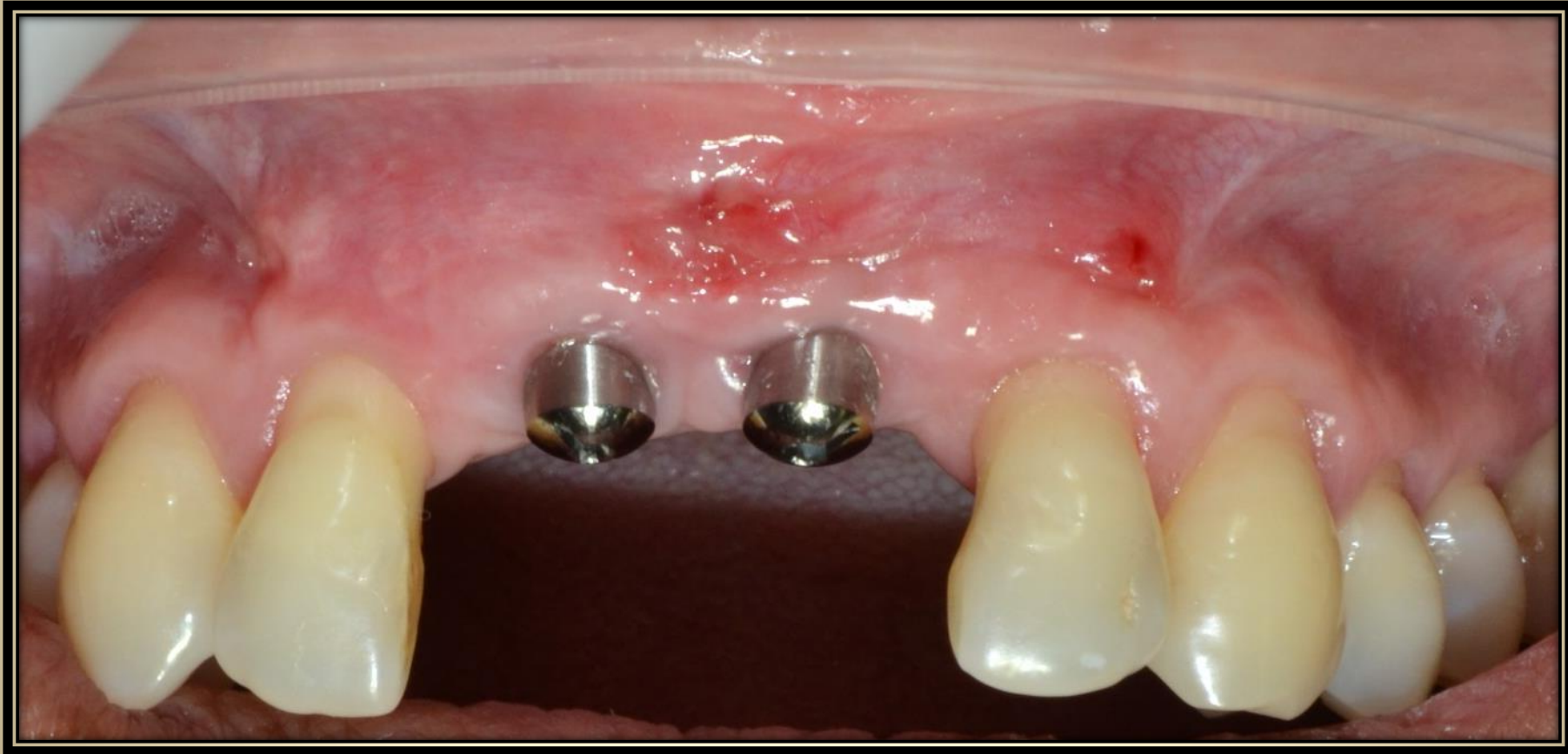7 días.

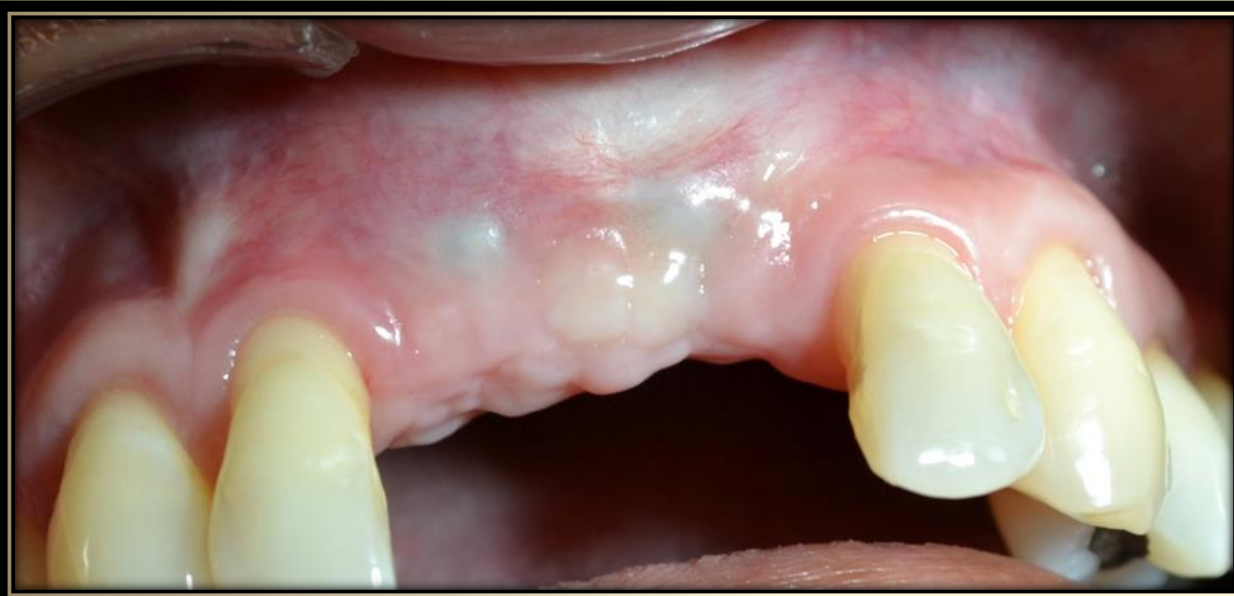

7 días.

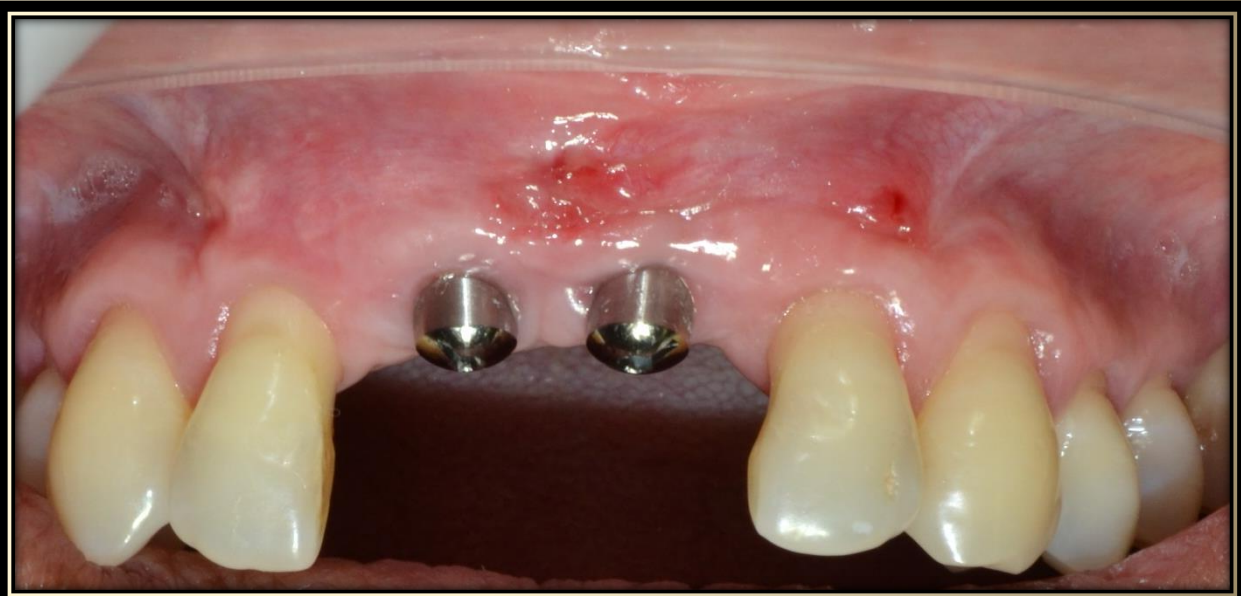
15 días postquirúrgicos.



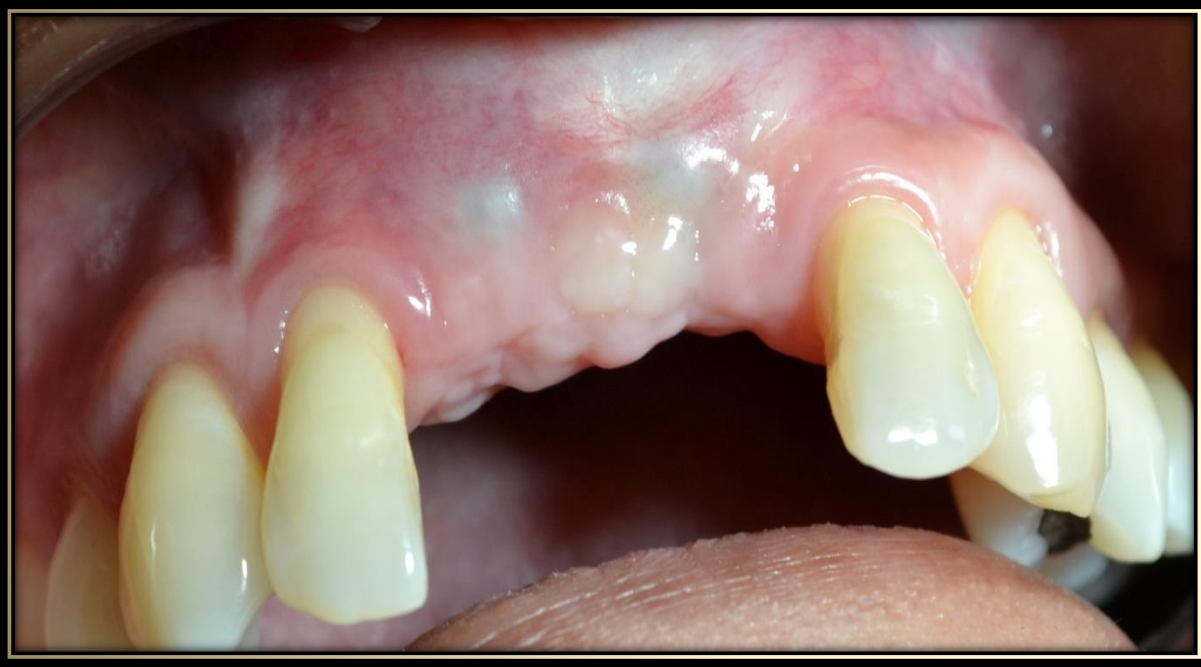▪ ANTES



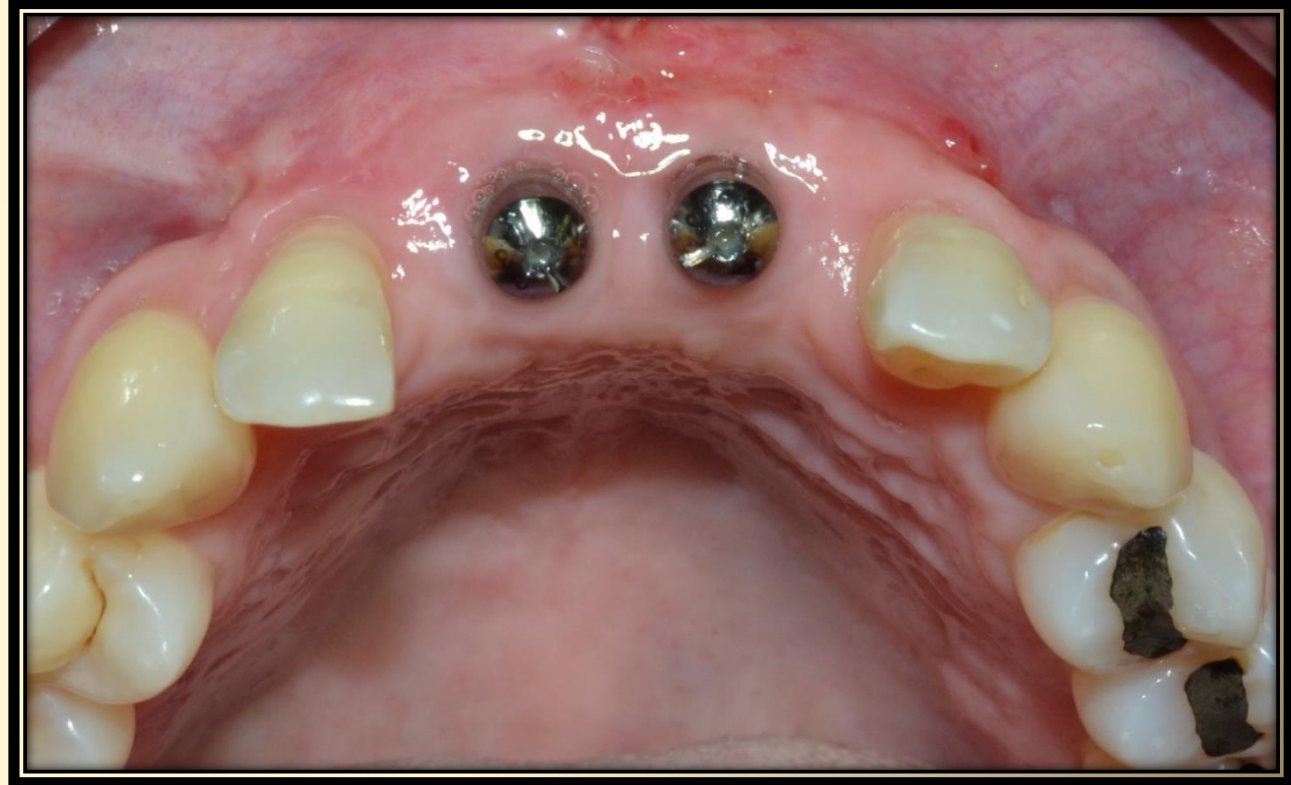▪ DESPUÉS



▪ ANTES





▪ DESPUÉS



REHABILITACIÓN.

▪ IMPRESIÓN.

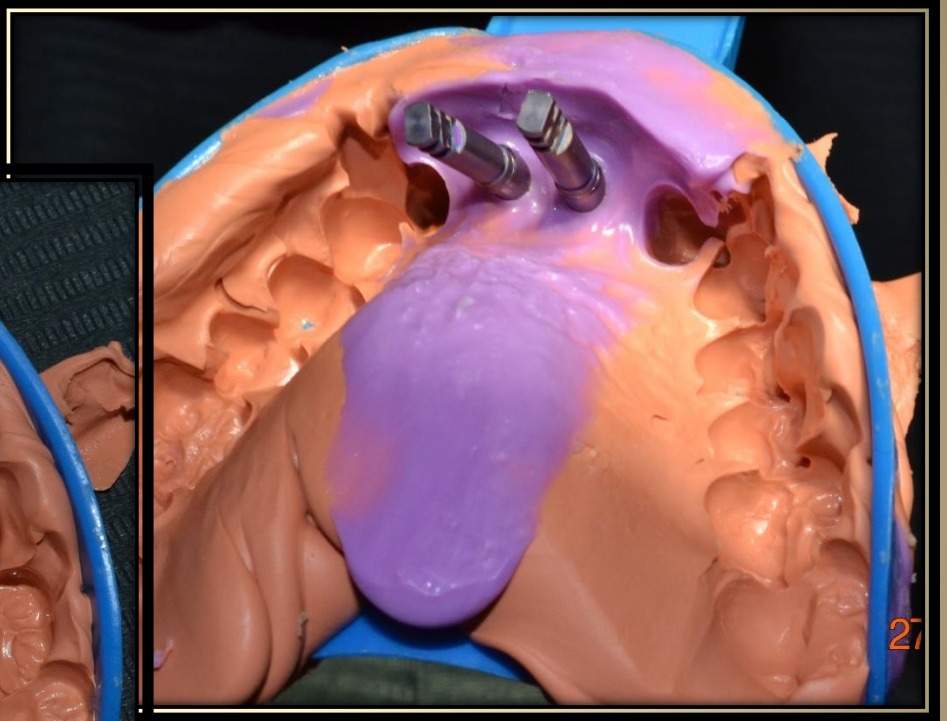
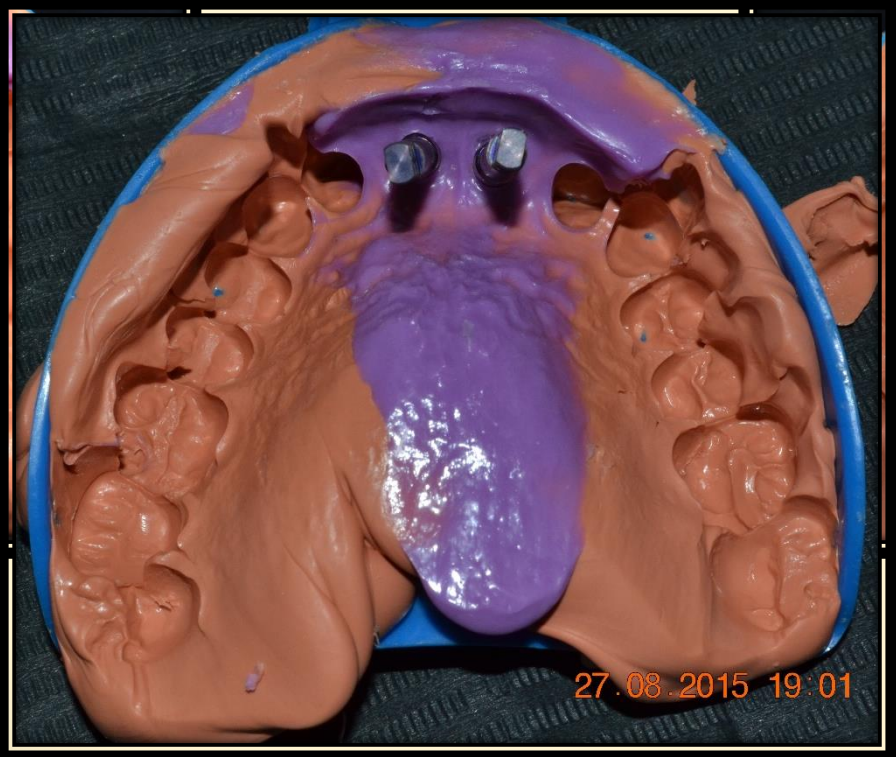
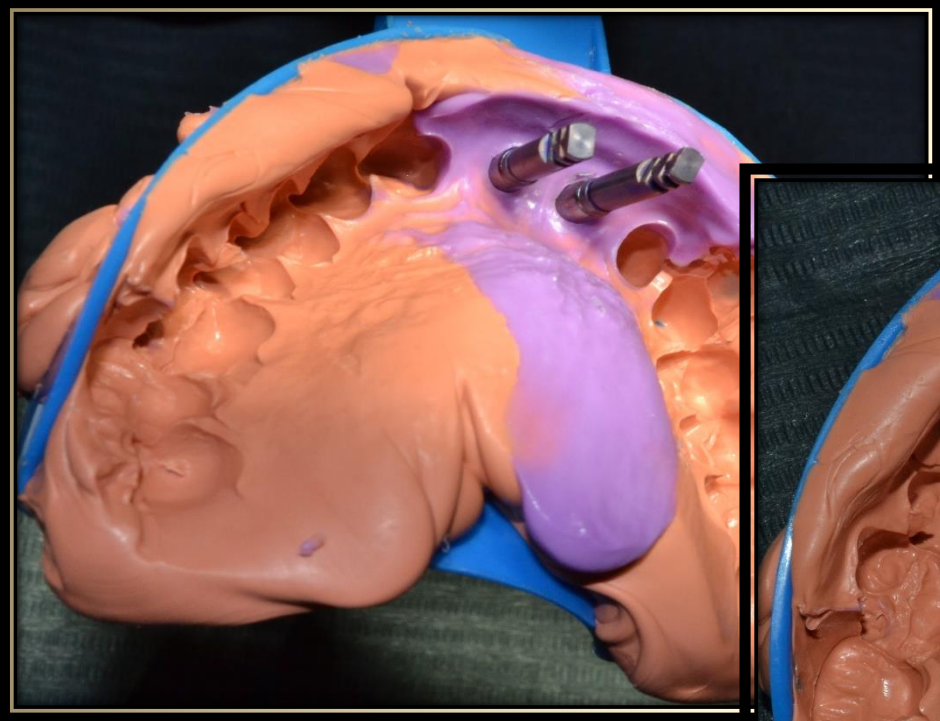


Transfer.

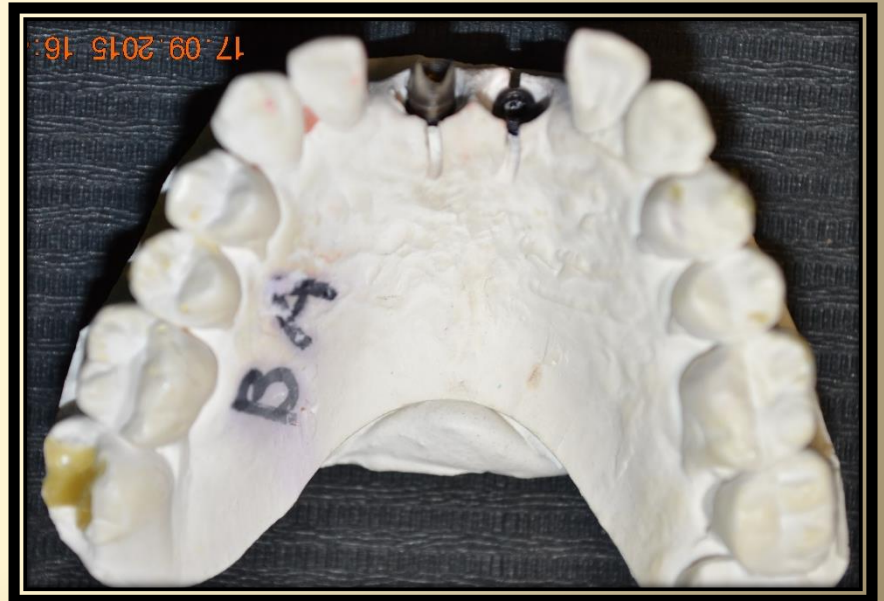
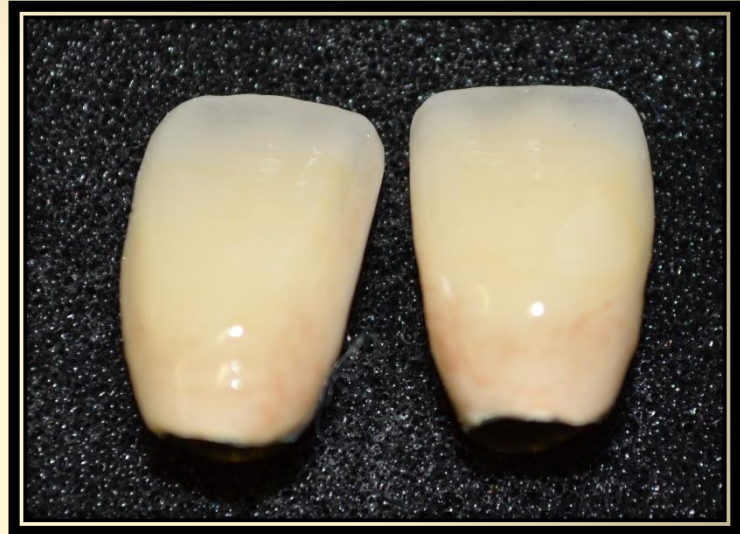Análogo.

Aditamento.

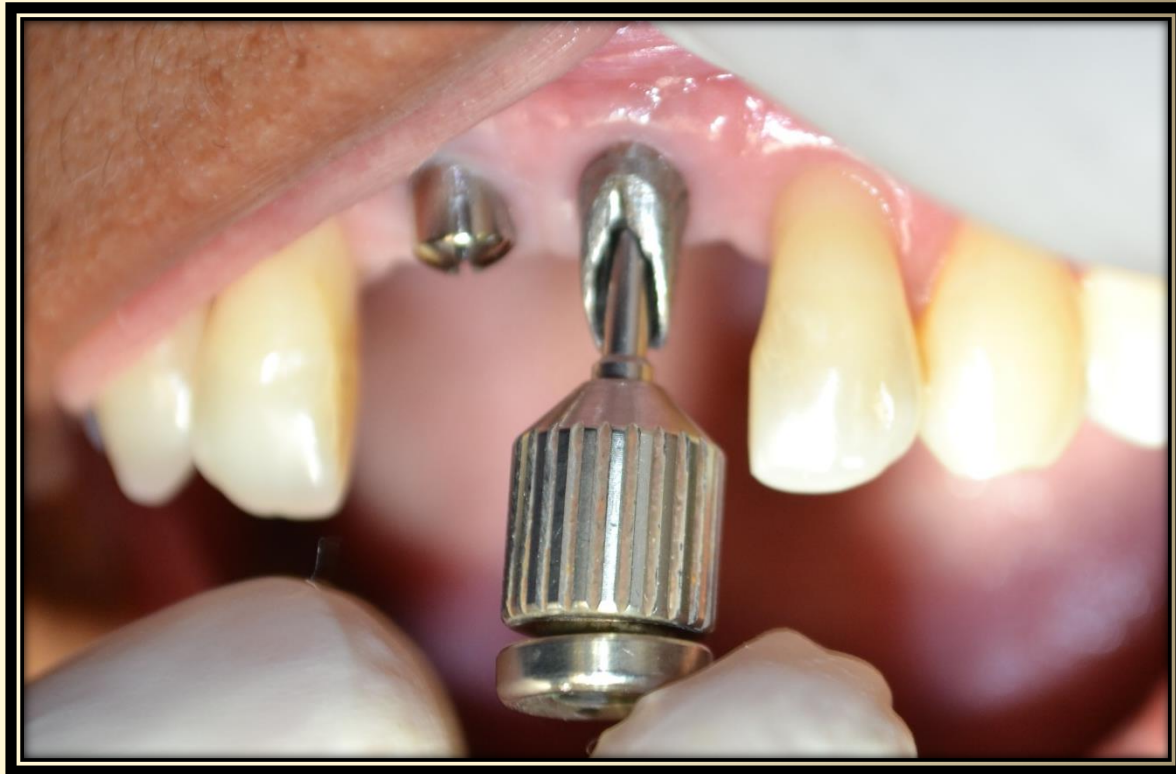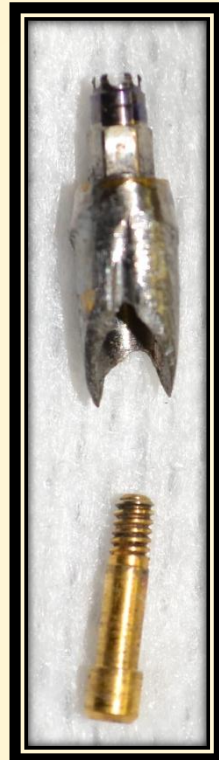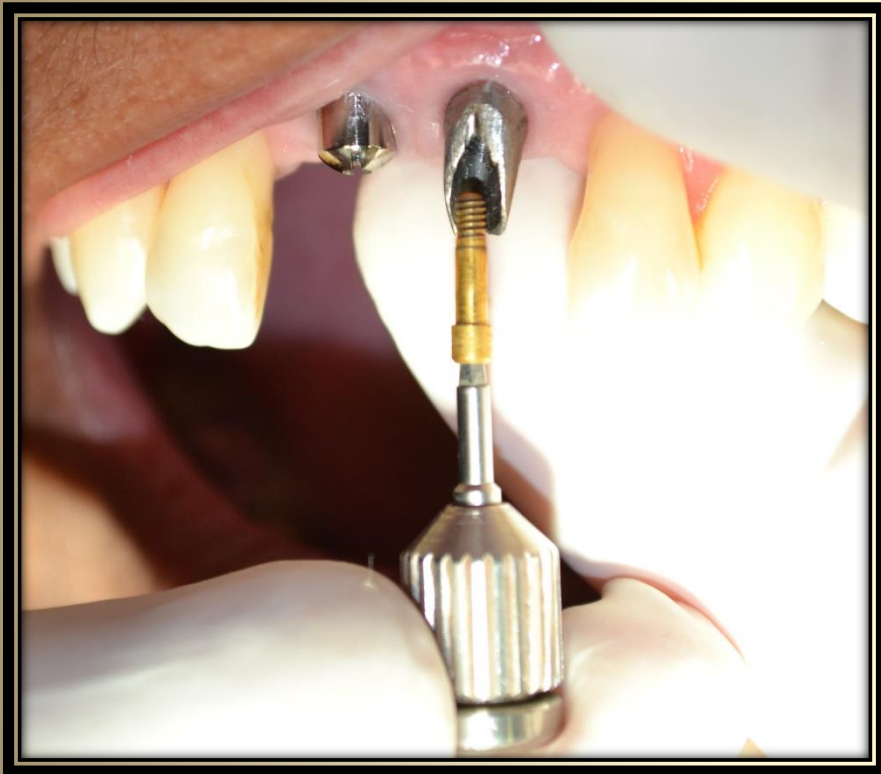▪ IMPRESIÓN.



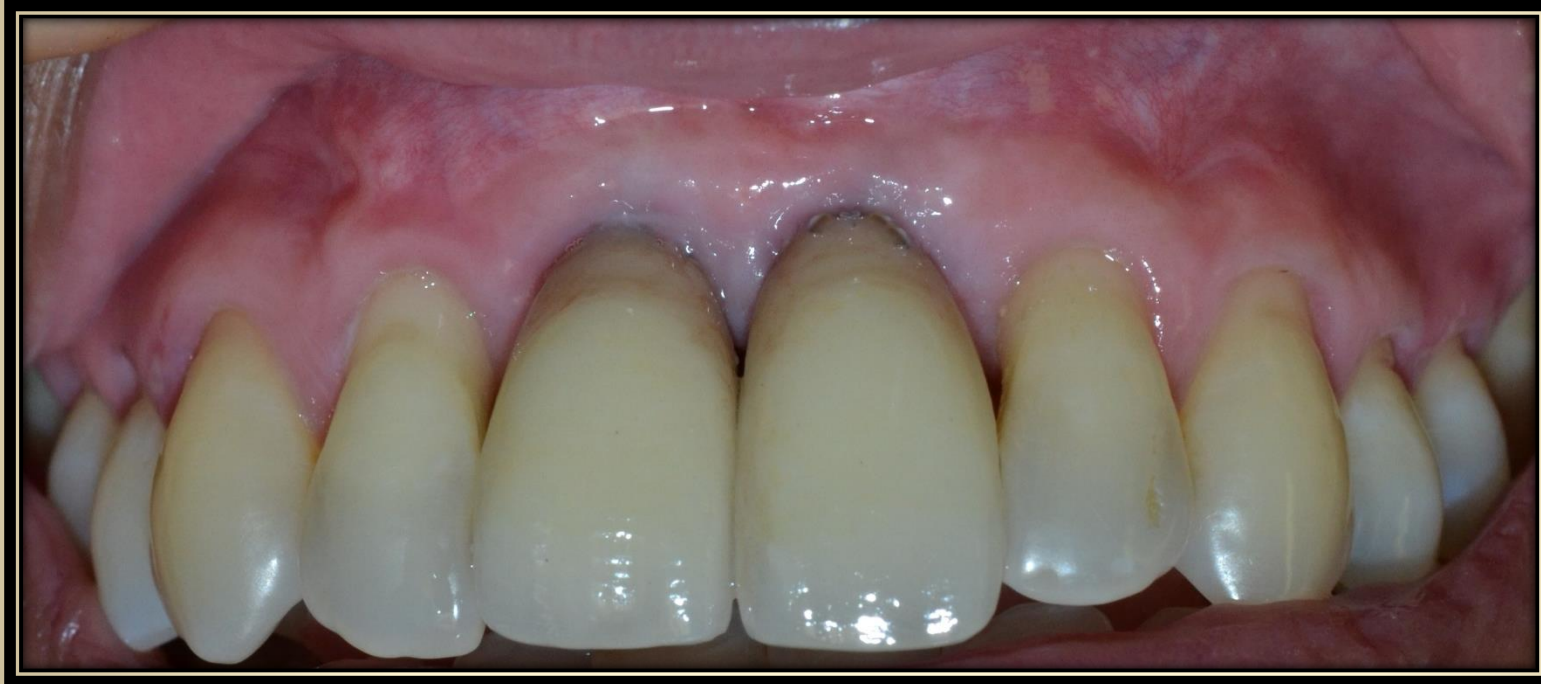REHABILITACIÓN.



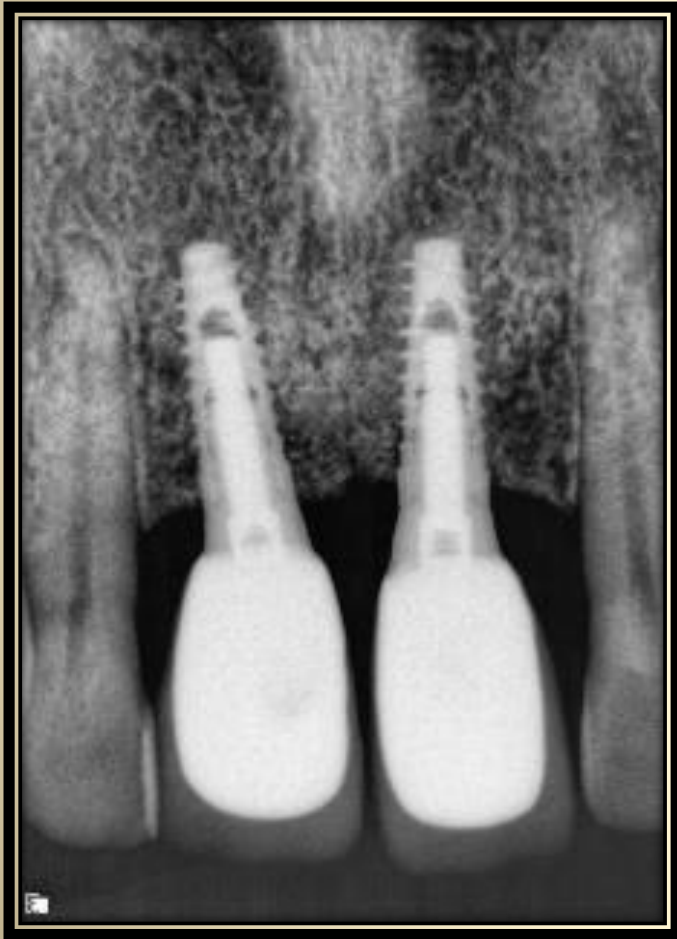
▪ REHABILITACIÓN.



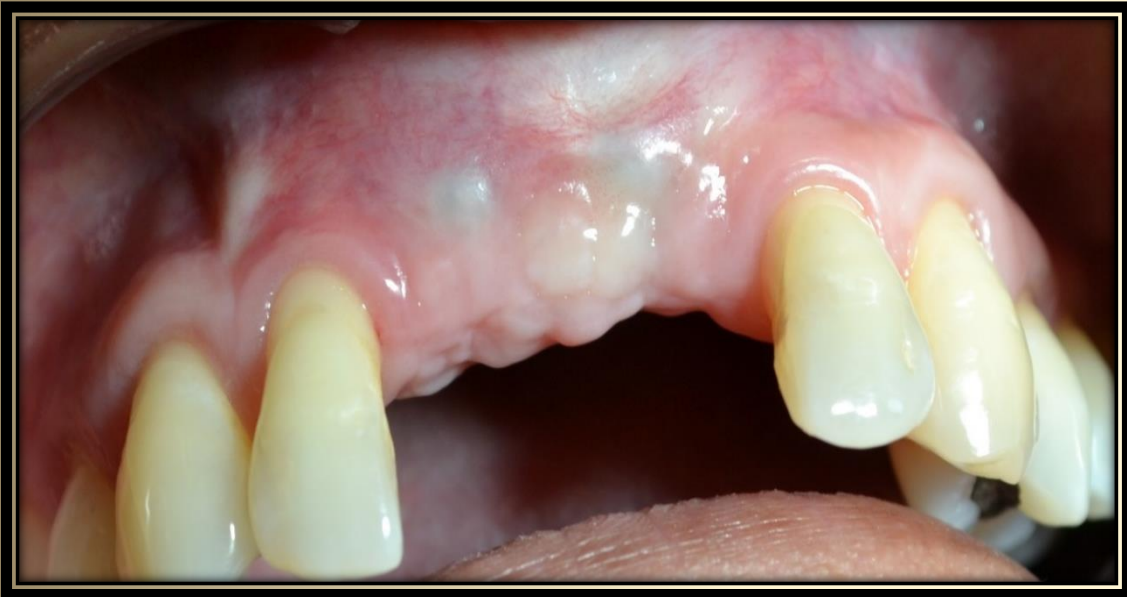- REHABILITACIÓN.



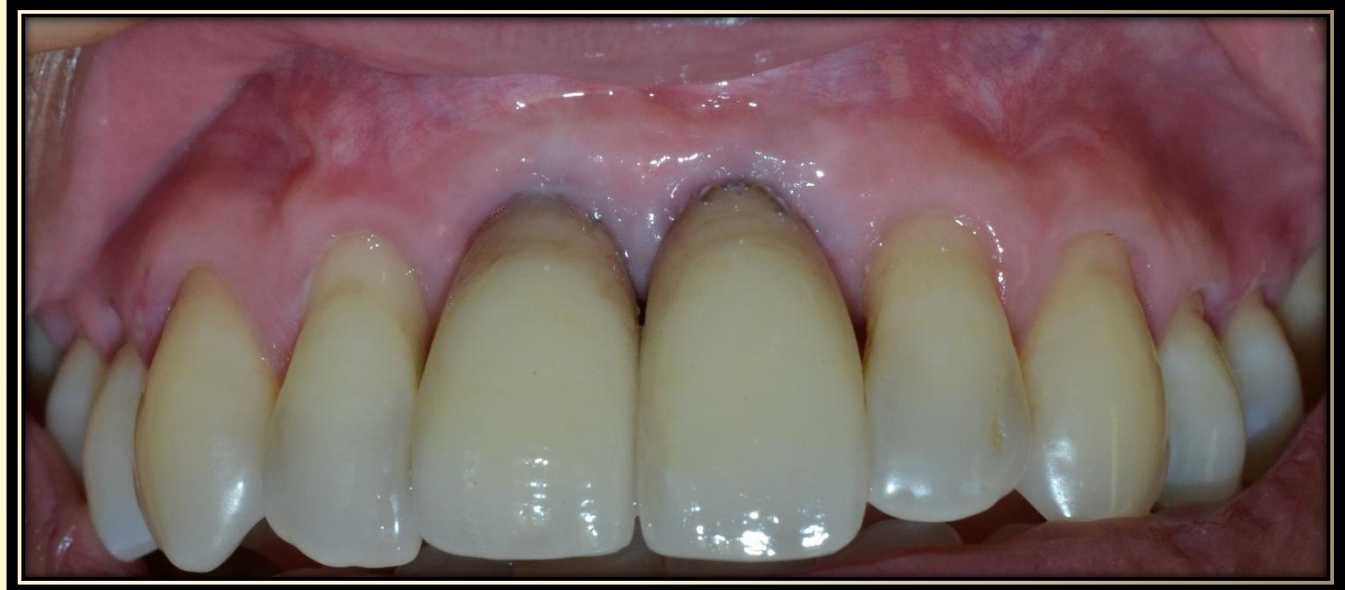▪ Rx.

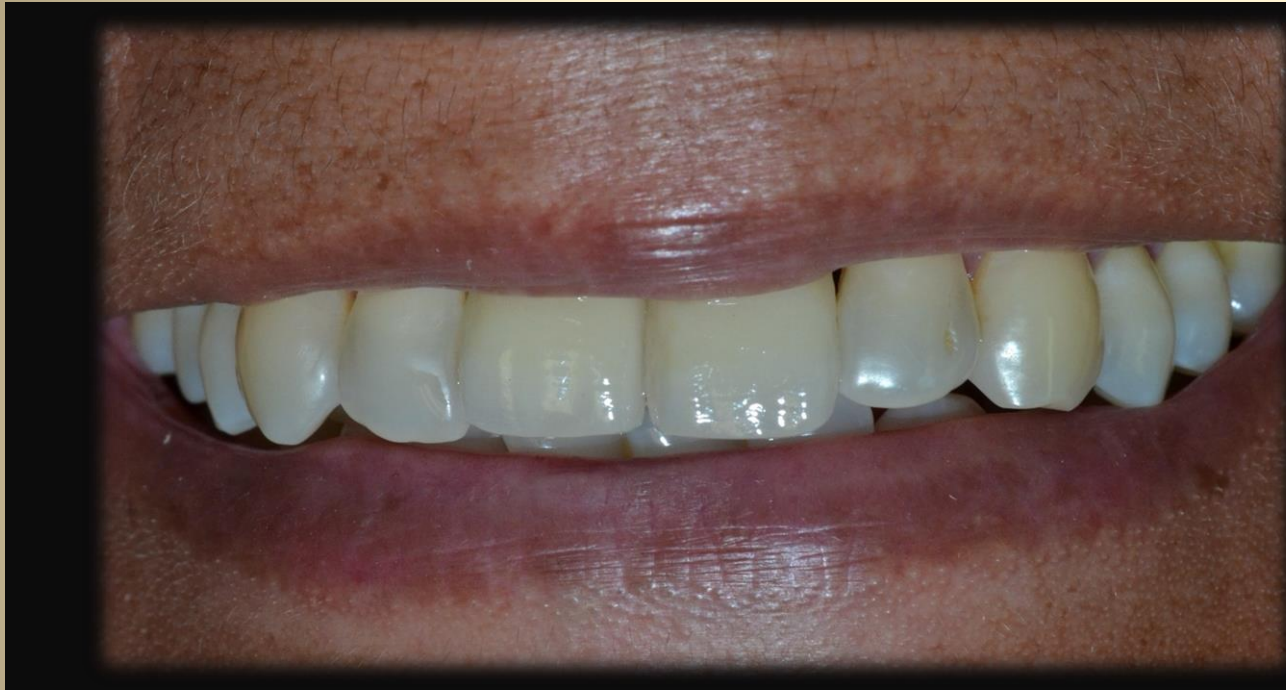

▪ ANTES



▪ DESPUÉS





CONCLUSIONES.

- La solución de casos de implantes mal posicionados.
 - Colocación de implantes con pobre o nula planeación prequirúrgica.
- Es importante familiarizarse con las formas de corregir este tipo de casos.
 - Se presentan de manera regular en la consulta diaria.

“...some failure in life is inevitable.

It is impossible to live without failing at something, unless you live so cautiously that you might as well not have lived at all – in which case, you fail by default.”

J.K. Rowling



Gracias...